A PUBLICATION BY REVIEW of OPHTHALMOLOGY

RETINA® SPECIALIST

VOL. 9, NO. 2 • MARCH/APRIL 2023

RAISING THE BAR FOR RRD REPAIR

Multimodal imaging and the potential of imaging biomarkers as outcome measures post-rhegmatogenous retinal detachment.

Page 28

Also Inside

Online Video

Discover continuous calm in uveitis[1]

YUTIQ is designed to deliver a sustained release of fluocinolone for up to 36 months for patients with chronic non-infectious uveitis affecting the posterior segment of the eye[1]

- **Proven to reduce uveitis recurrence at 6 and 12 months[1,*]**
  At 6 months–18% for YUTIQ and 79% for sham for Study 1 and 22% for YUTIQ and 54% for sham for Study 2 (*P*<.01). At 12 months–28% for YUTIQ and 86% for sham for Study 1 and 33% for YUTIQ and 60% for sham for Study 2.
- **Extended median time to first recurrence of uveitis[1,2]**
  At 12 months–NE[†] for YUTIQ/92 days for sham in Study 1; NE for YUTIQ/187 days for sham in Study 2.
- **Mean intraocular pressure (IOP) increase was comparable to sham[1,2]**
  Study was not sized to detect statistically significant differences in mean IOP.

*Study design: The efficacy of YUTIQ was assessed in 2 randomized, multicenter, sham-controlled, double-masked, Phase 3 studies in adult patients (N=282) with non-infectious uveitis affecting the posterior segment of the eye. The primary endpoint in both studies was the proportion of patients who experienced recurrence of uveitis in the study eye within 6 months of follow-up; recurrence was also assessed at 12 months. Recurrence was defined as either deterioration in visual acuity, vitreous haze attributable to non-infectious uveitis, or the need for rescue medications.

†NE=non-evaluable due to the low number of recurrences in the YUTIQ group.

For more information, visit

YUTIQ.com

INDICATIONS AND USAGE

YUTIQ® (fluocinolone acetonide intravitreal implant) 0.18 mg is indicated for the treatment of chronic non-infectious uveitis affecting the posterior segment of the eye.

IMPORTANT SAFETY INFORMATION

CONTRAINDICATIONS

Ocular or Periocular Infections: YUTIQ is contraindicated in patients with active or suspected ocular or periocular infections including most viral disease of the cornea and conjunctiva including active epithelial herpes simplex keratitis (dendritic keratitis), vaccinia, varicella, mycobacterial infections and fungal diseases.

Hypersensitivity: YUTIQ is contraindicated in patients with known hypersensitivity to any components of this product.

WARNINGS AND PRECAUTIONS

Intravitreal Injection-related Effects: Intravitreal injections, including those with YUTIQ, have been associated with endophthalmitis, eye inflammation, increased or decreased intraocular pressure, and choroidal or retinal detachments. Hypotony has been observed within 24 hours of injection and has resolved within 2 weeks. Patients should be monitored following the intravitreal injection.

Steroid-related Effects: Use of corticosteroids including YUTIQ may produce posterior subcapsular cataracts, increased intraocular pressure and glaucoma. Use of corticosteroids may enhance the establishment of secondary ocular infections due to bacteria, fungi, or viruses. Corticosteroids are not recommended to be used in patients with a history of ocular herpes simplex because of the potential for reactivation of the viral infection.

Risk of Implant Migration: Patients in whom the posterior capsule of the lens is absent or has a tear are at risk of implant migration into the anterior chamber.

ADVERSE REACTIONS

In controlled studies, the most common adverse reactions reported were cataract development and increases in intraocular pressure.

Please see brief summary of full Prescribing Information on adjacent page.

References: 1. YUTIQ® (fluocinolone acetonide intravitreal implant) 0.18 mg full US Prescribing Information. EyePoint Pharmaceuticals, Inc. February 2022. **2.** Data on file.

EYEPOINT® PHARMACEUTICALS

YUTIQ® (fluocinolone acetonide intravitreal implant) 0.18 mg, for intravitreal injection
Initial U.S. Approval: 1963

BRIEF SUMMARY: Please see package insert for full prescribing information.

1. INDICATIONS AND USAGE. YUTIQ® (fluocinolone acetonide intravitreal implant) 0.18 mg is indicated for the treatment of chronic non-infectious uveitis affecting the posterior segment of the eye.

4. CONTRAINDICATIONS. 4.1. Ocular or Periocular Infections. YUTIQ is contraindicated in patients with active or suspected ocular or periocular infections including most viral disease of the cornea and conjunctiva including active epithelial herpes simplex keratitis (dendritic keratitis), vaccinia, varicella, mycobacterial infections and fungal diseases. **4.2. Hypersensitivity.** YUTIQ is contraindicated in patients with known hypersensitivity to any components of this product.

5. WARNINGS AND PRECAUTIONS. 5.1. Intravitreal Injection-related Effects. Intravitreal injections, including those with YUTIQ, have been associated with endophthalmitis, eye inflammation, increased or decreased intraocular pressure, and choroidal or retinal detachments. Hypotony has been observed within 24 hours of injection and has resolved within 2 weeks. Patients should be monitored following the intravitreal injection *[see Patient Counseling Information (17) in the full prescribing information]*. **5.2. Steroid-related Effects.** Use of corticosteroids including YUTIQ may produce posterior subcapsular cataracts, increased intraocular pressure and glaucoma. Use of corticosteroids may enhance the establishment of secondary ocular infections due to bacteria, fungi, or viruses. Corticosteroids are not recommended to be used in patients with a history of ocular herpes simplex because of the potential for reactivation of the viral infection. **5.3. Risk of Implant Migration.** Patients in whom the posterior capsule of the lens is absent or has a tear are at risk of implant migration into the anterior chamber.

6. ADVERSE REACTIONS. 6.1. Clinical Studies Experience. Because clinical trials are conducted under widely varying conditions, adverse reaction rates observed in the clinical trials of a drug cannot be directly compared to rates in the clinical trials of another drug and may not reflect the rates observed in practice. Adverse reactions associated with ophthalmic steroids including YUTIQ include cataract formation and subsequent cataract surgery, elevated intraocular pressure, which may be associated with optic nerve damage, visual acuity and field defects, secondary ocular infection from pathogens including herpes simplex, and perforation of the globe where there is thinning of the cornea or sclera. Studies 1 and 2 were multicenter, randomized, sham injection-controlled, masked trials in which patients with non-infectious uveitis affecting the posterior segment of the eye were treated once with either YUTIQ or sham injection, and then received standard care for the duration of the study. Study 3 was a multicenter, randomized, masked trial in which patients with non-infectious uveitis affecting the posterior segment of the eye were all treated once with YUTIQ, administered by one of two different applicators, and then received standard care for the duration of the study. Table 1 summarizes data available from studies 1, 2 and 3 through 12 months for study eyes treated with YUTIQ (n=226) or sham injection (n=94). The most common ocular (study eye) and non-ocular adverse reactions are shown in Table 1 and Table 2.

Table 1: Ocular Adverse Reactions Reported in ≥ 1% of Subject Eyes and Non-Ocular Adverse Reactions Reported in ≥ 2% of Patients

Ocular		
ADVERSE REACTIONS	**YUTIQ (N=226 Eyes) n (%)**	**Sham Injection (N=94 Eyes) n (%)**
Cataract[1]	63/113 (56%)	13/56 (23%)
Visual Acuity Reduced	33 (15%)	11 (12%)
Macular Edema	25 (11%)	33 (35%)
Uveitis	22 (10%)	33 (35%)
Conjunctival Hemorrhage	17 (8%)	5 (5%)
Eye Pain	17 (8%)	12 (13%)
Hypotony Of Eye	16 (7%)	1 (1%)
Anterior Chamber Inflammation	12 (5%)	6 (6%)
Dry Eye	10 (4%)	3 (3%)
Vitreous Opacities	9 (4%)	8 (9%)
Conjunctivitis	9 (4%)	5 (5%)
Posterior Capsule Opacification	8 (4%)	3 (3%)
Ocular Hyperemia	8 (4%)	7 (7%)
Vitreous Haze	7 (3%)	4 (4%)
Foreign Body Sensation In Eyes	7 (3%)	2 (2%)
Vitritis	6 (3%)	8 (9%)
Vitreous Floaters	6 (3%)	5 (5%)
Eye Pruritus	6 (3%)	5 (5%)
Conjunctival Hyperemia	5 (2%)	2 (2%)
Ocular Discomfort	5 (2%)	1 (1%)
Macular Fibrosis	5 (2%)	2 (2%)
Glaucoma	4 (2%)	1 (1%)
Photopsia	4 (2%)	2 (2%)
Vitreous Hemorrhage	4 (2%)	0
Iridocyclitis	3 (1%)	7 (7%)
Eye Inflammation	3 (1%)	2 (2%)
Choroiditis	3 (1%)	1 (1%)
Eye Irritation	3 (1%)	1 (1%)
Visual Field Defect	3 (1%)	0
Lacrimation Increased	3 (1%)	0
Non-ocular		
ADVERSE REACTIONS	**YUTIQ (N=214 Patients) n (%)**	**Sham Injection (N=94 Patients) n (%)**
Nasopharyngitis	10 (5%)	5 (5%)
Hypertension	6 (3%)	1 (1%)
Arthralgia	5 (2%)	1 (1%)

(continued)

Table 1: Ocular Adverse Reactions Reported in ≥ 1% of Subject Eyes and Non-Ocular Adverse Reactions Reported in ≥ 2% of Patients

1. Includes cataract, cataract subcapsular and lenticular opacities in study eyes that were phakic at baseline. 113 of the 226 YUTIQ study eyes were phakic at baseline; 56 of 94 sham-controlled study eyes were phakic at baseline.

Table 2: Summary of Elevated IOP Related Adverse Reactions

ADVERSE REACTIONS	**YUTIQ (N=226 Eyes) n (%)**	**Sham (N=94 Eyes) n (%)**
IOP elevation ≥ 10 mmHg from Baseline	50 (22%)	11 (12%)
IOP elevation > 30 mmHg	28 (12%)	3 (3%)
Any IOP-lowering medication	98 (43%)	39 (41%)
Any surgical intervention for elevated IOP	5 (2%)	2 (2%)

Figure 1: Mean IOP During the Studies

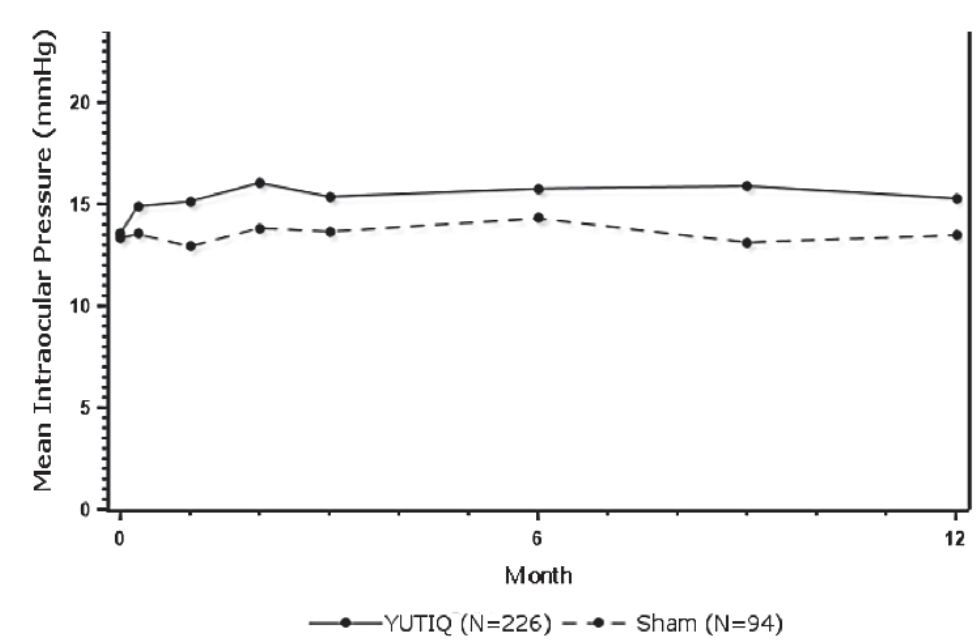

8. USE IN SPECIFIC POPULATIONS. 8.1 Pregnancy. Risk Summary. Adequate and well-controlled studies with YUTIQ have not been conducted in pregnant women to inform drug associated risk. Animal reproduction studies have not been conducted with YUTIQ. It is not known whether YUTIQ can cause fetal harm when administered to a pregnant woman or can affect reproduction capacity. Corticosteroids have been shown to be teratogenic in laboratory animals when administered systemically at relatively low dosage levels. YUTIQ should be given to a pregnant woman only if the potential benefit justifies the potential risk to the fetus. All pregnancies have a risk of birth defect, loss, or other adverse outcomes. In the United States general population, the estimated background risk of major birth defects and miscarriage in clinically recognized pregnancies is 2% to 4% and 15% to 20%, respectively. **8.2 Lactation.** Risk Summary. Systemically administered corticosteroids are present in human milk and can suppress growth, interfere with endogenous corticosteroid production. Clinical or nonclinical lactation studies have not been conducted with YUTIQ. It is not known whether intravitreal treatment with YUTIQ could result in sufficient systemic absorption to produce detectable quantities of fluocinolone acetonide in human milk, or affect breastfed infants or milk production. The developmental and health benefits of breastfeeding should be considered, along with the mother's clinical need for YUTIQ and any potential adverse effects on the breastfed child from YUTIQ. **8.4 Pediatric Use.** Safety and effectiveness of YUTIQ in pediatric patients have not been established. **8.5 Geriatric Use.** No overall differences in safety or effectiveness have been observed between elderly and younger patients.

Manufactured by:
EyePoint Pharmaceuticals US, Inc., 480 Pleasant Street, Watertown, MA 02472 USA
Patented. See https://eyepointpharma.com/patent-notification/

RETINA
SPECIALIST

19 Campus Blvd., Suite 101
Newtown Square, PA 19073
Telephone (610) 492-1000
Fax (610) 492-1039

Editorial inquiries (610) 492-1000
Advertising inquiries (610) 492-1011
E-mail retinaspecialist@jobson.com

Jobson Medical Information

EDITORIAL

By Charles C. Wykoff, MD, PhD



The complement era dawns

For generations, retina specialists have listened helplessly as patients with geographic atrophy described their frustrations about visual dysfunctions and anxieties about losing more vision. But our field wasn't idle through those years. Teams of researchers methodically built upon insights from genetics, pathology, immunology, ocular imaging and clinical observation, finally yielding a tangible option for patients.

Last month, with the Food and Drug Administration approval of pegcetacoplan (Syfovre, Apellis Pharmaceuticals) for treatment of GA, a new era dawned for retina. This is arguably the biggest innovation in retina care since anti-VEGF injections.

With this new era, we face a host of new challenges and uncertainties.

First, the efficacy benefit is modest. We would all like a drug that stopped GA growth, but that's not what we have, at least not on average through two years. Specifically, in the OAKS and DERBY Phase III registration trials involving 1,258 patients, pegcetacoplan reduced GA growth 17 to 20 percent, with a greater benefit among eyes with nonsubfoveal GA, at 22 to 26 percent. Most importantly, efficacy increased over time, with up to a 30 percent reduction in GA growth over months 18 to 24.

Simply put, this is a therapy that will likely need to be given indefinitely to yield maximal benefit, and there's currently no biomarker we can use to measure efficacy. It's important that patients understand these perspectives before they start therapy to appropriately set expectations.

Second, pegcetacoplan has key side effects to recognize that appear dose-dependent. New wet AMD was diagnosed in 12, 7 and 3 percent of monthly, every-other-month and sham patients. Ideally, patients receive optical coherence tomography imaging regularly to screen for any evidence of exudation so that they can efficiently start anti-VEGF therapy when needed.

Ischemic optic neuropathy was diagnosed in 1.7, 0.2 and 0 percent of the aforementioned arms, respectively. While we need more data about these patients, and data from large numbers of patients treated in routine clinical practice will likely prove valuable to better define and understand this potential risk signal, at this time one might consider every-othr-month dosing, particularly among patients at risk of ION due to a disc at risk and/or other factors.

Practically, the volume and viscosity of pegcetacoplan are unique. Pegcetacoplan is a viscous fluid delivered as 100 µL. It requires substantially more time to draw into the syringe than our anti-VEGF agents. Be patient and use a Luer Lock syringe. Then, make sure the entire dose is delivered intravitreally before withdrawing the needle. Also, consider approaches to minimize intraocular pressure fluctuations, especially in high-risk eyes.

The FDA-approval of pegcetacoplan validates complement as a therapeutic target in GA. It's an exciting time in retina and we're going to learn much more about pegcetacoplan and GA as we go forward. RS



A PUBLICATION BY REVIEW of OPHTHALMOLOGY

RETINA SPECIALIST

MARCH/APRIL 2023 • VOL. 9, NO. 2

FEATURES

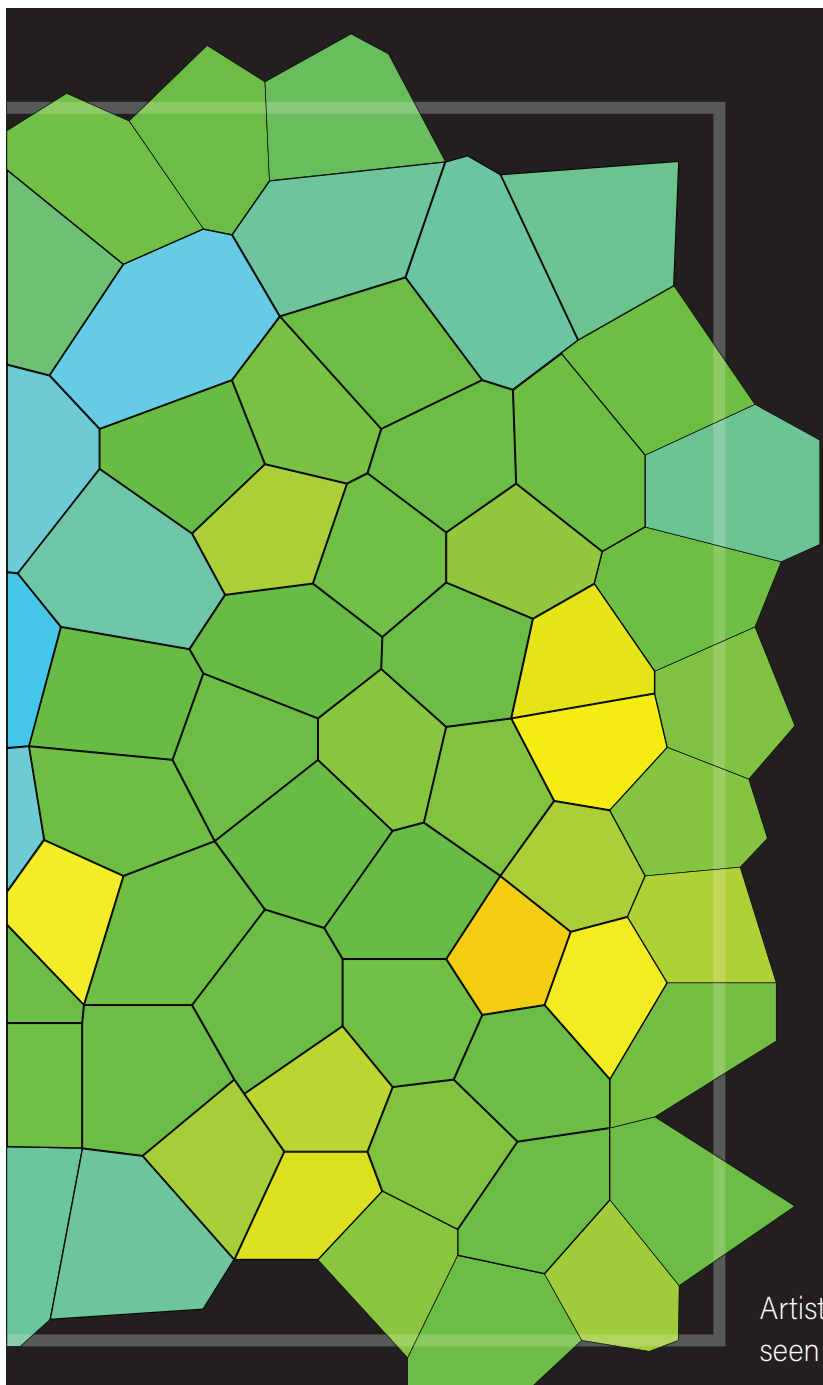

Artist's rendering. Colors may differ from those seen in the clinic due to printing requirements.

DEPARTMENTS

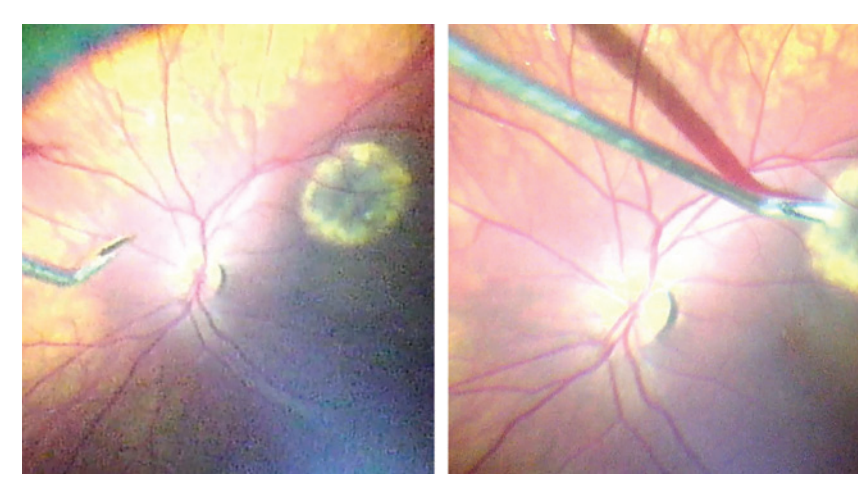

NOW APPROVED: the first and only FDA-approved treatment for GA secondary to AMD[1]

GA unravels so much
SAVE RETINAL TISSUE BY SLOWING PROGRESSION[1-3]

SYFOVRE achieved continuous reductions in mean lesion growth rate* vs sham pooled from baseline to Month 24[1]

Monthly	Every Other Month (EOM)
OAKS trial (mm^2): (3.11 vs 3.98) **22%**	OAKS trial (mm^2): (3.26 vs 3.98) **18%**
DERBY trial (mm^2): (3.28 vs 4.00) **18%**	DERBY trial (mm^2): (3.31 vs 4.00) **17%**

SE in trials (monthly, EOM, sham pooled): OAKS: 0.15, 0.13, 0.14; DERBY: 0.13, 0.13, 0.17.

*Slope for baseline to Month 24 is an average of slope of baseline to Month 6, Month 6 to Month 12, Month 12 to Month 18, and Month 18 to Month 24.[1]
Based on a mixed effects model for repeated measures assuming a piecewise linear trend in time with knots at Month 6, Month 12, and Month 18.[1]

AMD=age-related macular degeneration; GA=geographic atrophy; SE=standard error.

Learn more about the SYFOVRE clinical data at
SyfovreECP.com/efficacy

INDICATION

SYFOVRE™ (pegcetacoplan injection) is indicated for the treatment of geographic atrophy (GA) secondary to age-related macular degeneration (AMD).

IMPORTANT SAFETY INFORMATION

CONTRAINDICATIONS

- SYFOVRE is contraindicated in patients with ocular or periocular infections, and in patients with active intraocular inflammation

WARNINGS AND PRECAUTIONS

- **Endophthalmitis and Retinal Detachments**
  - Intravitreal injections, including those with SYFOVRE, may be associated with endophthalmitis and retinal detachments. Proper aseptic injection technique must always be used when administering SYFOVRE to minimize the risk of endophthalmitis. Patients should be instructed to report any symptoms suggestive of endophthalmitis or retinal detachment without delay and should be managed appropriately.
- **Neovascular AMD**
  - In clinical trials, use of SYFOVRE was associated with increased rates of neovascular (wet) AMD or choroidal neovascularization (12% when administered monthly, 7% when administered every other month and 3% in the control group) by Month 24. Patients receiving SYFOVRE should be monitored for signs of neovascular AMD. In case anti-Vascular Endothelial Growth Factor (anti-VEGF) is required, it should be given separately from SYFOVRE administration.
- **Intraocular Inflammation**
  - In clinical trials, use of SYFOVRE was associated with episodes of intraocular inflammation including: vitritis, vitreal cells, iridocyclitis, uveitis, anterior chamber cells, iritis, and anterior chamber flare. After inflammation resolves, patients may resume treatment with SYFOVRE.
- **Increased Intraocular Pressure**
  - Acute increase in IOP may occur within minutes of any intravitreal injection, including with SYFOVRE. Perfusion of the optic nerve head should be monitored following the injection and managed as needed.

ADVERSE REACTIONS

- Most common adverse reactions (incidence ≥5%) are ocular discomfort, neovascular age-related macular degeneration, vitreous floaters, conjunctival hemorrhage.

Please see Brief Summary of Prescribing Information for SYFOVRE on the adjacent page.

Trial Design: SYFOVRE safety and efficacy were assessed in OAKS (N=637) and DERBY (N=621), multi-center, 24-month, Phase 3, randomized, double-masked trials. Patients with GA (atrophic nonexudative age-related macular degeneration), with or without subfoveal involvement, secondary to AMD were randomly assigned (2:2:1:1) to receive 15 mg/0.1 mL intravitreal SYFOVRE monthly, SYFOVRE EOM, sham monthly, or sham EOM for 24 months. Change from baseline in the total area of GA lesions in the study eye (mm^2) was measured by fundus autofluorescence (FAF).[1,4]

References: 1. SYFOVRE (pegcetacoplan injection) [package insert]. Waltham, MA: Apellis Pharmaceuticals, Inc.; 2023. **2.** Pfau M, von der Emde L, de Sisternes L, et al. Progression of photoreceptor degeneration in geographic atrophy secondary to age-related macular degeneration. *JAMA Ophthalmol.* 2020;138(10):1026-1034. **3.** Bird AC, Phillips RL, Hageman GS. Geographic atrophy: a histopathological assessment. *JAMA Ophthalmol.* 2014;132(3):338-345. **4.** Data on file. Apellis Pharmaceuticals, Inc.

Apellis

SYFOVRE™
(pegcetacoplan injection)
15 mg / 0.1 mL

SYFOVRE ™ (pegcetacoplan injection), for intravitreal use
BRIEF SUMMARY OF PRESCRIBING INFORMATION
Please see SYFOVRE full Prescribing Information for details.

INDICATIONS AND USAGE

SYFOVRE is indicated for the treatment of geographic atrophy (GA) secondary to age-related macular degeneration (AMD).

CONTRAINDICATIONS

Ocular or Periocular Infections
SYFOVRE is contraindicated in patients with ocular or periocular infections.
Active Intraocular Inflammation
SYFOVRE is contraindicated in patients with active intraocular inflammation.

WARNINGS AND PRECAUTIONS

Endophthalmitis and Retinal Detachments
Intravitreal injections, including those with SYFOVRE, may be associated with endophthalmitis and retinal detachments. Proper aseptic injection technique must always be used when administering SYFOVRE in order to minimize the risk of endophthalmitis. Patients should be instructed to report any symptoms suggestive of endophthalmitis or retinal detachment without delay and should be managed appropriately.
Neovascular AMD
In clinical trials, use of SYFOVRE was associated with increased rates of neovascular (wet) AMD or choroidal neovascularization (12% when administered monthly, 7% when administered every other month and 3% in the control group) by Month 24. Patients receiving SYFOVRE should be monitored for signs of neovascular AMD. In case anti-Vascular Endothelial Growth Factor (anti-VEGF) is required, it should be given separately from SYFOVRE administration.
Intraocular Inflammation
In clinical trials, use of SYFOVRE was associated with episodes of intraocular inflammation including: vitritis, vitreal cells, iridocyclitis, uveitis, anterior chamber cells, iritis, and anterior chamber flare. After inflammation resolves patients may resume treatment with SYFOVRE.
Increased Intraocular Pressure
Acute increase in IOP may occur within minutes of any intravitreal injection, including with SYFOVRE. Perfusion of the optic nerve head should be monitored following the injection and managed as needed.

ADVERSE REACTIONS

Clinical Trials Experience
Because clinical trials are conducted under widely varying conditions, adverse reaction rates observed in the clinical trials of a drug cannot be directly compared to rates in the clinical trials of another drug and may not reflect the rates observed in practice.
A total of 839 patients with GA in two Phase 3 studies (OAKS and DERBY) were treated with intravitreal SYFOVRE, 15 mg (0.1 mL of 150 mg/mL solution). Four hundred nineteen (419) of these patients were treated in the affected eye monthly and 420 were treated in the affected eye every other month. Four hundred seventeen (417) patients were assigned to sham.
The most common adverse reactions (≥5%) reported in patients receiving SYFOVRE were ocular discomfort, neovascular age-related macular degeneration, vitreous floaters, and conjunctival hemorrhage.
Table 1: Adverse Reactions in Study Eye Reported in ≥2% of Patients Treated with SYFOVRE Through Month 24 in Studies OAKS and DERBY

Adverse Reactions	PM (N = 419) %	PEOM (N = 420) %	Sham Pooled (N = 417) %
Ocular discomfort*	13	10	11
Neovascular age-related macular degeneration*	12	7	3
Vitreous floaters	10	7	1
Conjunctival hemorrhage	8	8	4
Vitreous detachment	4	6	3
Retinal hemorrhage	4	5	3
Punctate keratitis*	5	3	<1
Posterior capsule opacification	4	4	3
Intraocular inflammation*	4	2	<1
Intraocular pressure increased	2	3	<1

PM: SYFOVRE monthly; PEOM: SYFOVRE every other month
*The following reported terms were combined:
Ocular discomfort included: eye pain, eye irritation, foreign body sensation in eyes, ocular discomfort, abnormal sensation in eye
Neovascular age-related macular degeneration included: exudative age-related macular degeneration, choroidal neovascularization
Punctate keratitis included: punctate keratitis, keratitis
Intraocular inflammation included: vitritis, vitreal cells, iridocyclitis, uveitis, anterior chamber cells, iritis, anterior chamber flare

Endophthalmitis, retinal detachment, hyphema and retinal tears were reported in less than 1% of patients. Optic ischemic neuropathy was reported in 1.7% of patients treated monthly, 0.2% of patients treated every other month and 0.0% of patients assigned to sham. Deaths were reported in 6.7% of patients treated monthly, 3.6% of patients treated every other month and 3.8% of patients assigned to sham. The rates and causes of death were consistent with the elderly study population.

USE IN SPECIFIC POPULATIONS

Pregnancy
Risk Summary
There are no adequate and well-controlled studies of SYFOVRE administration in pregnant women to inform a drug-associated risk. The use of SYFOVRE may be considered following an assessment of the risks and benefits.
Systemic exposure of SYFOVRE following ocular administration is low. Subcutaneous administration of pegcetacoplan to pregnant monkeys from the mid gestation period through birth resulted in increased incidences of abortions and stillbirths at systemic exposures 1040-fold higher than that observed in humans at the maximum recommended human ophthalmic dose (MRHOD) of SYFOVRE (based on the area under the curve (AUC) systemically measured levels). No adverse maternal or fetal effects were observed in monkeys at systemic exposures approximately 470-fold higher than that observed in humans at the MRHOD.
In the U.S. general population, the estimated background risk of major birth defects and miscarriage in clinically recognized pregnancies is 2-4% and 15-20%, respectively.
Lactation
Risk Summary
It is not known whether intravitreal administered pegcetacoplan is secreted in human milk or whether there is potential for absorption and harm to the infant. Animal data suggest that the risk of clinically relevant exposure to the infant following maternal intravitreal treatment is minimal. Because many drugs are excreted in human milk, and because the potential for absorption and harm to infant growth and development exists, caution should be exercised when SYFOVRE is administered to a nursing woman.
Females and Males of Reproductive Potential
Contraception
Females: It is recommended that women of childbearing potential use effective contraception methods to prevent pregnancy during treatment with intravitreal pegcetacoplan. Advise female patients of reproductive potential to use effective contraception during treatment with SYFOVRE and for 40 days after the last dose. For women planning to become pregnant, the use of SYFOVRE may be considered following an assessment of the risks and benefits.
Pediatric Use
The safety and effectiveness of SYFOVRE in pediatric patients have not been established.
Geriatric Use
In clinical studies, approximately 97% (813/839) of patients randomized to treatment with SYFOVRE were ≥ 65 years of age and approximately 72% (607/839) were ≥ 75 years of age. No significant differences in efficacy or safety were seen with increasing age in these studies. No dosage regimen adjustment is recommended based on age.

PATIENT COUNSELING INFORMATION

Advise patients that following SYFOVRE administration, patients are at risk of developing neovascular AMD, endophthalmitis, and retinal detachments. If the eye becomes red, sensitive to light, painful, or if a patient develops any change in vision such as flashing lights, blurred vision or metamorphopsia, instruct the patient to seek immediate care from an ophthalmologist.
Patients may experience temporary visual disturbances associated either with the intravitreal injection with SYFOVRE or the eye examination. Advise patients not to drive or use machinery until visual function has recovered sufficiently.

Manufactured for:
Apellis Pharmaceuticals, Inc.
100 Fifth Avenue
Waltham, MA 02451

SYF-PI-17Feb2023-1.0

2/23 US-PEGGA-2200163 v2.0

With FDA approval, pegcetacoplan launches with high awareness—and a few questions

Pegcetacoplan injection (Syfovre, Apellis Pharmaceuticals) is launching with a high awareness among ophthalmologists, according to a pulse study conducted shortly after the drug's historic approval.

However, it seems retina specialists are taking a nuanced approach to using the new treatment in their practices, the study, which Spherix Global Insights conducted, found. And even with the approval, not all retina specialists will be embracing the new treatment with open arms.

Issues with pegcetacoplan

Demetrios Vavvas, MD, PhD, associate retina service director at Massachusetts Eye and Ear in Boston, has been a vocal critic of the new treatment. Among the key findings from the pivotal OAKS and DERBY trials that Dr. Vavvas takes issue with:

- The reported 20 percent reduction across the monthly (PM) and every-other-month (PEOM) treatment arms. Dr. Vavvas says the actual reduction is 7.4 percent, and that the reported reduction is based on predicted lesion growth.
- Pegcetacoplan offers no meaningful benefit for best-corrected visual acuity. He notes that BCVA declined about seven letters in sham eyes, about eight letters in the PM arm and about nine letters in the PEOM group.
- The 12.2 percent of PM eyes that converted to neovascular, or exudative, age-related macular degeneration at two years, is about four times the rate in the sham group and almost double the rate of PEOM eyes.

But two OAKS/DERBY investigators take issue with his interpretation of the results.

Different views of results

"The reductions in GA lesion growth of 21 percent with pegcetacoplan every month and 17 percent with every-other month are actual reductions vs. sham over 24 months," says Sunir Garg, MD, codirector of retina research at Wills Eye Hospital, Philadelphia, and an OAKS/DERBY investigator. The model for calculating that reduction, the mixed effects model for repeated measures (MMRM), "is a well-accepted statistical model for assessing longitudinal data." He notes that pivotal trials for lampalizumab and faricimab used the same modeling.

Dr. Garg adds that when patients with nonsubfoveal lesions were segregated from the overall cohort, the GA area reductions were even more robust: 26 percent with PM and 22 percent with PEOM treatment.

With regard to the rates of eAMD, Philip Ferrone, MD, a retina specialist in Great Neck, N.Y., says they're similar to the conversion rates with other complement inhibitors. "In OAKS/DERBY, eAMD rates are higher with PM than with PEOM, but when comparing rates at one year of pegcetacoplan vs. those of other complement inhibitors, the rates are the same—approximately 6 percent with monthly dosing. The one-year rate with PEOM dosing, however, is lower—4.1 percent." At two years, the conversion rate more than doubled in the PM group.

> **SOME KEY FACTS ABOUT PEGCETACOPLAN**
>
> - It's approved for geographic atrophy with or without subfoveal involvement.
> - It has a flexible dosing regimen of every 25 to 60 days.
> - It'll cost $2,190 per vial.

He notes the "vast majority" of OAKS/DERBY patients that converted to eAMD had treatment with anti-VEGF agents. "The average number of injections per month following the diagnosis of eAMD was approximately 0.5, or one injection every two months, with no difference in pegcetacoplan-treated and sham patients," Dr. Ferrone says.

Who benefits? It depends

Obviously, the three retina specialists have differing views on who would benefit from the treatment. Dr. Vavvas says he won't offer pegcetacoplan to any patient. "So if a patient comes in and asks you, 'Will I see any benefit?' the answer is no," he says. "There

RETINA SPECIALIST

BUSINESS OFFICES
19 CAMPUS BOULEVARD, SUITE 101
NEWTOWN SQUARE, PA 19073
SUBSCRIPTION INQUIRIES (877) 529-1746
(USA ONLY); OUTSIDE USA, CALL (847) 763-9630

BUSINESS STAFF
PUBLISHER
MICHAEL HOSTER
(610) 492-1028 MHOSTER@JOBSON.COM

SENIOR MANAGER, STRATEGIC ACCOUNTS
MICHELE BARRETT
(610) 492-1014 MBARRETT@JOBSON.COM

REGIONAL SALES MANAGER
JONATHAN DARDINE
(610) 492-1030 JDARDINE@JOBSON.COM

CLASSIFIED ADVERTISING
(888)-498-1460

PRODUCTION MANAGER
KAREN LALLONE
(610) 492-1010 KLALLONE@JOBSON.COM

SUBSCRIPTIONS
US ONE YEAR: $63.00
CANADIAN ONE YEAR: $99.00
FOREIGN ONE YEAR: $158.00
SUBSCRIPTIONS E-MAIL:
SUBSCRIPTIONS@MDEDGE.COM

CIRCULATION
RETINA SPECIALIST
10255 W HIGGINS ROAD, SUITE 280
ROSEMONT, IL 60018.

DIRECTOR, CIRCULATION
JARED SONNERS
jsonners@mdedge.com

CEO, INFORMATION GROUP SERVICES
BILL SCOTT

SENIOR VICE PRESIDENT, OPERATIONS
JEFF LEVITZ

VICE PRESIDENT, HUMAN RESOURCES
TAMMY GARCIA

VICE PRESIDENT, CREATIVE SERVICES & PRODUCTION
MONICA TETTAMANZI

SENIOR CORPORATE PRODUCTION DIRECTOR
JOHN ANTHONY CAGGIANO

DIRECTOR, CIRCULATION
JARED SONNERS

Jobson Medical Information LLC,
395 Hudson Street, 3rd Floor, New York, NY 10014

is no improvement in any symptoms or quality of life or any functional index that was tested."

Dr. Garg points out that OAKS/DERBY showed efficacy in all lesion types. "The nonsubfoveal subgroup had even more robust effects, with a 26 percent reduction with monthly and 22 percent reduction with every-other- month treatment," he says.

Dr. Ferrone concurs, noting that OAKS/DERBY enrolled "a broad population of GA patients."

The Spherix Global Insights study reports that surveyed ophthalmologists are most inclined to use pegcetacoplan in patients with significant vision loss in one eye and foveal involvement in the other. However, they're less confident about using it in eyes that also have eAMD, citing wariness about the idea of two intravitreal injections in the same eye on the same day.

And so the ascent of the learning curve for pegcetacoplan begins.

Dr. Vavvas has no relevant disclosures. Dr. Garg and Dr. Ferrone are investigators for Apellis.

– Richard Mark Kirkner

Retina Specialist editorial board welcomes two new columnists

Retina Specialist magazine has expanded its editorial board with the addition of two new columnists. They are:

Tina Felfeli, MD, an ophthalmology resident at the University of Toronto and a long-time contributor to the "North of the Border" column, has taken over as department editor of "Surgical Video Pearl," picking up where Paul Hahn, MD, PhD, leaves off after launching the column eight years ago.

Jayanth Sridhar, MD, an associate professor of clinical ophthalmology at Bascom Palmer Eye Institute, Miami, joins as the magazine's Social Media Ambassador. He's also taking over the "Social Media Specialist" column that David R.P. Almeida, MD, PhD, MBA, had penned for the past four years.

Dr. Hahn and Dr. Almeida will continue on as editorial board members.

IN BRIEF

The Food and Drug Administration has accepted **8-mg aflibercept (Regeneron Pharmaceuticals)**, otherwise known as high-dose aflibercept, for priority review for the treatment of age-related macular degeneration and diabetic macular edema. The FDA has set a target action date of July 27, 2023.

The FDA also approved **Eylea**, the 2-mg formulation of aflibercept, for treatment of retinopathy of prematurity in preterm infants. It's the first FDA-approved anti-VEGF treatment for the disease.

The Centers for Medicare and Medicaid Services has granted a new product-specific Q code for **Cimerli (Coherus BioSciences)**, a ranibizumab biosimilar. The Q-code will be effective on or after April 1, 2023.

The first patient has been dosed in the trial of **FT-002 (Frontera Therapeutics)**, a gene therapy for treatment of X-linked retinitis pigmentosa.

AI for the vitreoretinal surgeon

What's in the pipeline, how it may change practice and what a chatbot has to say about it.

By Daniel Lamoureux, Tina Felfeli, MD, and Efrem D. Mandelcorn, MD, FRCSC


Daniel Lamoureux


Tina Felfeli, MD


Efrem D. Mandelcorn, MD, FRCSC

With the recent news of Google investing $300 million to compete against the artificial intelligence chatbot ChatGPT, we decided to put together a list of some of the exciting advances of artificial intelligence in vitreoretinal surgery. Although it would certainly be convenient to use ChatGPT to generate this article (*box, page 12*), we conducted our own research on this topic. Here's what we found in five different pathology areas and about how AI is impacting surgical training and assistance.

Diabetic retinopathy

Diabetic retinopathy screening has shown great potential to benefit from the integration of AI. Devices for AI-based DR grading can function in two modes:[1]


Figure 1. Notal Vision's ForeseeHome, invented and made in Israel, allows critical at-home daily monitoring of a disease that can quickly lead to vision loss. (*Courtesy Notal Vision*)

- ***Assistive (augmented intelligence) mode.*** In this mode, an ophthalmologist reviews the grading the device provides and can adjust or accept it based on their level of agreement.
- ***Fully automatic mode.*** This mode doesn't allow for ophthalmologist review of the images. Based on the evaluation of multimodal images, the machine sends referable DR and ungradeable images directly to the ophthalmologist.

Studies have shown promising results for the use of these technologies, particularly in countries with high diabetes rates.[2] In countries such as Singapore, analyses have estimated that this technology will produce yearly cost savings upwards of $15 million by 2050.[3]

This technology won't only benefit vitreoretinal surgeons and their patients, but also allow them to screen more patients in a more time-efficient manner, helping them to triage patients who require prompt intervention.

Age-related macular degeneration

AI algorithms have proven to be effective in detecting age-related macular degeneration using optical coherence tomography images, with a patient-level accuracy of 93 percent.[4] The ongoing RAZORBILL study is exploring how AI algorithms can assist in treatment decisions for patients with neovascular AMD by analyzing three-dimensional OCT scans and extracting relevant features for provider review.[5]

AI can also predict the need for anti-VEGF treatment and a patient's likely response to therapy.[6,7] Based on OCT images, visual acuity and demographic characteristics, it may also play a pivotal role in the discovery of novel treatments for AMD, along

BIOS

Mr. Lamoureux is a medical student at the Northern Ontario School of Medicine, Thunder Bay.

Dr. Felfeli is an ophthalmology resident at the University of Toronto.

Dr. Mandelcorn is an associate professor of ophthalmology at the University of Toronto.

DISCLOSURES: The authors have no relevant financial disclosures.

with other ophthalmic diseases.

AI has demonstrated utility in the development and design of pharmaceuticals, with applications in molecular design, toxicity prediction and many other areas of the drug design process.[8] Additionally, it has been utilized for the complex analysis of intraocular biomarkers and the correlation of cytokines profiles in ocular diseases.[9,10]

In terms of devices, the ForeseeHome (Notal Vision) AMD monitoring system is a home-based device that patients can operate independently (*Figure 1, page 11*). It uses AI to detect statistically significant changes from a patient's baseline and alerts providers of these results.[11]

This device proved to be beneficial in minimizing a decline in visual acuity from baseline to choroidal neovascularization detection.[12] Similar to the DR screening applications, this technology allows for optimal management of patients and ensures that patients progressing to a further stage of their disease receive prompt attention and treatment.

Retinal detachment

AI may be applied to ophthalmic ultrasonography to screen patients with retinal detachment.[13] AI models can analyze still images and videos of ultrasonography scans and determine if they show an RD, vitreous detachment, vitreous hemorrhage or tears, with an accuracy of 90 percent or higher in all categories.

Deep-learning models also have implications for predicting anatomical outcomes of RD postoperatively with an area under the curve (AUC) of 0.94, sensitivity of 73 percent and a specificity of 96 percent.[14]

Lastly, a screening algorithm has been developed to analyze ultra-widefield fundus images for RD detection, including the distinction between macula-on and macula-off RD.[15] Interestingly, the algorithm could also provide guidance to patients regarding head

AI models can analyze still images and videos of ultrasonography scans and determine if they show an RD, vitreous detachment, vitreous hemorrhage or other lesions, with an accuracy of 90 percent or higher in all categories.

ChatGPT's AI-generated response about AI's potential in vitreoretinal surgery

ChatGPT prompt: *Regarding artificial intelligence for vitreoretinal surgeons, what is in the pipeline and how will it change their practices?*

AI-generated response: There is a growing interest in the use of artificial intelligence (AI) in vitreoretinal surgery, as it has the potential to improve surgical outcomes and increase efficiency. The following are some examples of AI applications in this field:

1. ***Image analysis:*** AI algorithms can be trained to analyze retinal images to identify features such as blood vessels, retinal detachments and age-related macular degeneration. This information can assist surgeons in making more informed decisions about the best treatment approach.

2. ***Surgical planning and navigation:*** AI can be used to assist in surgical planning by analyzing images of the eye and creating a personalized surgical plan based on the anatomy of the eye and the specific disease being treated. Additionally, AI-powered navigation systems can be used during surgery to help guide the surgeon and improve accuracy.

3. ***Predictive modeling:*** AI algorithms can be trained to predict the outcomes of surgical procedures, allowing surgeons to make informed decisions about the best approach for each patient.

4. ***Real-time surgical assistance:*** AI can be integrated into surgical equipment, such as handheld devices, to provide real-time feedback and guidance during surgery. This can improve accuracy and safety, and reduce the time needed for each procedure.

Overall, AI has the potential to greatly enhance the practice of vitreoretinal surgery by improving surgical outcomes, increasing efficiency, and reducing the risk of complications. As more AI applications are developed and validated, it is likely that they will become an increasingly important tool for vitreoretinal surgeons.

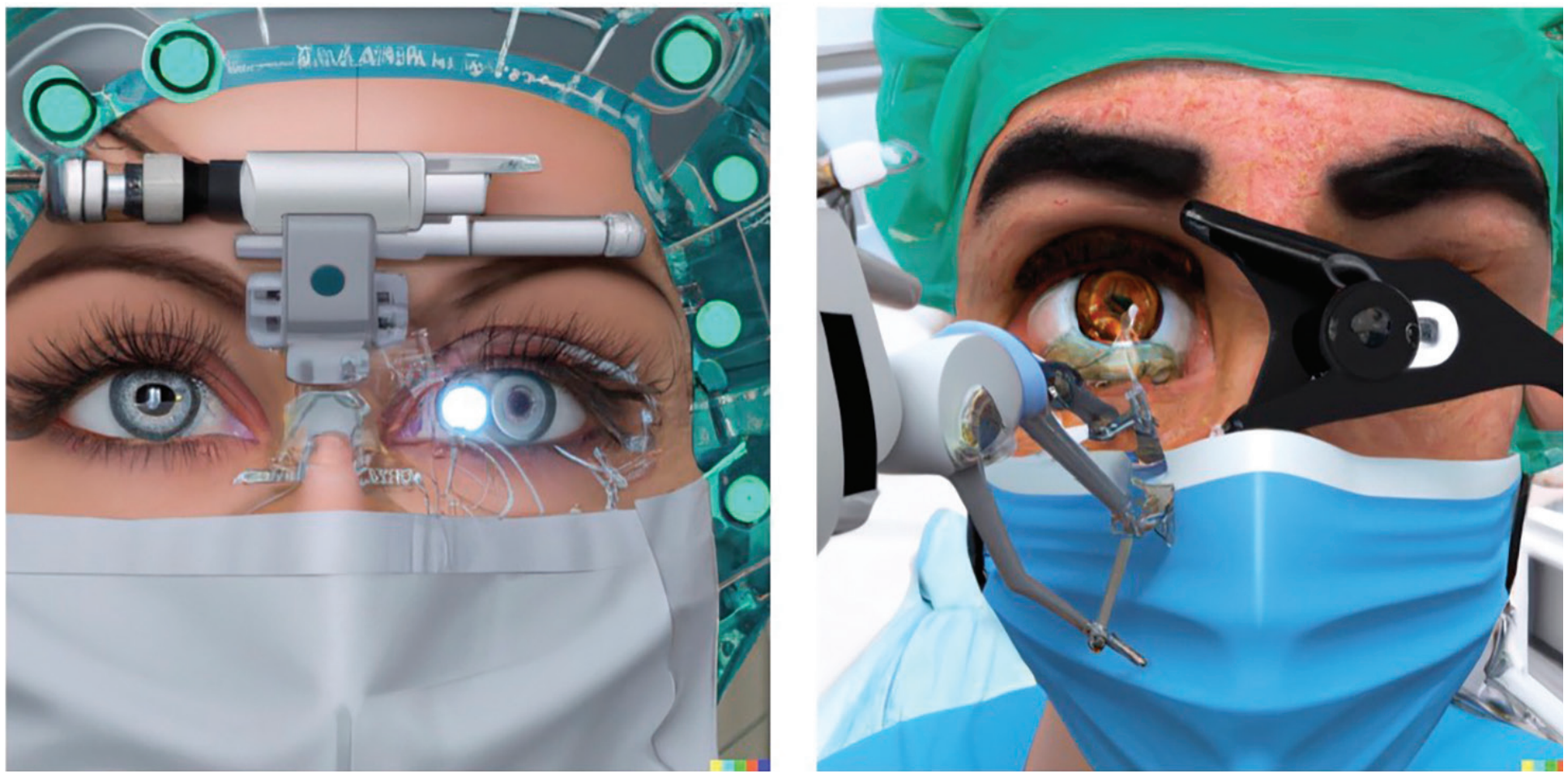

Figure 2. Artificial intelligence-generated art provided courtesy of DALL-E 2, using the prompt, "3D rendering of vitreoretinal surgeon using artificial intelligence while doing eye surgery."

positioning, which could minimize the progression of their RD prior to surgical repair.

Macular hole

Studies of AI applications in macular hole diagnosis and management show great promise and represent a crucial step toward the widespread adoption of this technology in the future. Researchers in China developed a deep-learning model to predict postoperative macular hole status after internal limiting membrane peeling.[16]

The model made these predictions using preoperative OCT images and achieved an accuracy of 84.7 percent in external validation, with an AUC of 89.32 percent (sensitivity of 83.33 percent and specificity of 87.5 percent). Researchers in Italy explored the potential of AI to predict the one-year visual acuity of eyes affected by full-thickness macular hole.[17] The predictions were based on preoperative OCT-A scans and the researchers evaluated various AI models to improve the results.

These studies highlight the potential of AI in predicting postoperative outcomes, which could help guide decision-making between providers and patients.

Epiretinal membrane

The applications of AI for diagnosis and management of epiretinal membrane have also been demonstrated. A recent study aimed to validate the use of AI to diagnose an ERM based on color fundus photographs.[18] The AI model produced encouraging results, with comparable accuracy and a higher sensitivity than manual diagnosis by an ophthalmologist based on fundus photographs alone (77.08 vs. 75.69 percent and 75.9 vs. 63.86 percent, respectively). Notably, the AI model had a lower specificity when compared with manual diagnosis (78.69 vs. 91.8 percent).

AI has also demonstrated its use for predicting long-term visual improvement after ERM surgery, based on OCT images.[19] The-deep learning model achieved a sensitivity of 87.3 percent and a specificity of 86.2 percent when predicting one-year visual outcomes for ERM patients who underwent surgical intervention.

AI has also demonstrated its use for predicting long-term visual improvement after epiretinal membrane surgery, based on OCT images.

Surgical training and assistance

The field of vitreoretinal surgery has seen significant advancements in AI with the integration of robotics, such as tremor reduction, other surgical assistive functions and surgical training devices (*Figure 2*).[20]

One study demonstrated that AI can be used in vitreoretinal procedures to localize,

(Continued on page 18)

Department Editor ***Lisa C. Olmos de Koo, MD, MBA***

Sympathetic to the cause

A long-ago ocular trauma caused a sympathetic panuveitis in the fellow eye.

By Sara L. Hojjatie MD, K. Matthew McKay MD, and Thellea Leveque MD, MPH

Sara L. Hojjatie MD

K. Matt McKay, MD

Thellea K. Leveque, MD, MPH

BIOS

Dr. Hojjatie is an ophthalmology resident at the University of Washington, Seattle.

Dr. McKay is a retina fellow the University of Washington.

Dr. Leveque is a clinical professor of ophthalmology at the University of Washington.

Dr. Olmos de Koo is an associate professor of ophthalmology at the University of Washington.

DISCLOSURES: The authors have no relevant financial disclosures.

UW Medicine EYE INSTITUTE

A 65-year-old male was referred to our tertiary care institution for intraocular inflammation of the right eye that didn't respond to topical steroids.

His ocular history was notable for a zone 1 and 2 open-globe injury of the left eye secondary to penetrating trauma from a metal screw several years earlier. After the open-globe injury was primarily repaired, he developed a retinal detachment that became recurrent with proliferative vitreoretinopathy. That required two additional surgeries for repair, including scleral buckle placement, pars plana vitrectomy with lensectomy and silicone oil tamponade.

His retinal detachment repair was ultimately successful with the injured left eye attaining 20/100 visual acuity.

At the time of his presentation, he was applying topical prednisolone four times daily in the right eye and twice daily in the left eye. He had not recently traveled outside of the United States.

Examination and imaging findings

His examination was notable for visual acuity of 20/20-2 in the right eye and no light perception in the left eye. Intraocular pressures were within normal limits in each eye. His right pupil was reactive, and his left pupil was 7 mm and fixed with a positive afferent pupillary defect by reverse.

Slit lamp exam of the right eye was notable for 1+ flare in the anterior chamber and 2-3+ vitreous cell. The fundus exam showed multifocal yellow subretinal lesions (*Figure 1*). The left eye conjunctiva was injected, and the view into the anterior chamber and fundus was limited secondary to dense corneal neovascularization, diffuse stromal edema and corneal scarring. The vitreous was replaced by silicone oil, precluding effective ultrasonography (*Figure 2*).

Optical coherence tomography of the right eye showed multiple focal and confluent retinal pigment epithelium elevations in a dome shape (*Figure 3*).

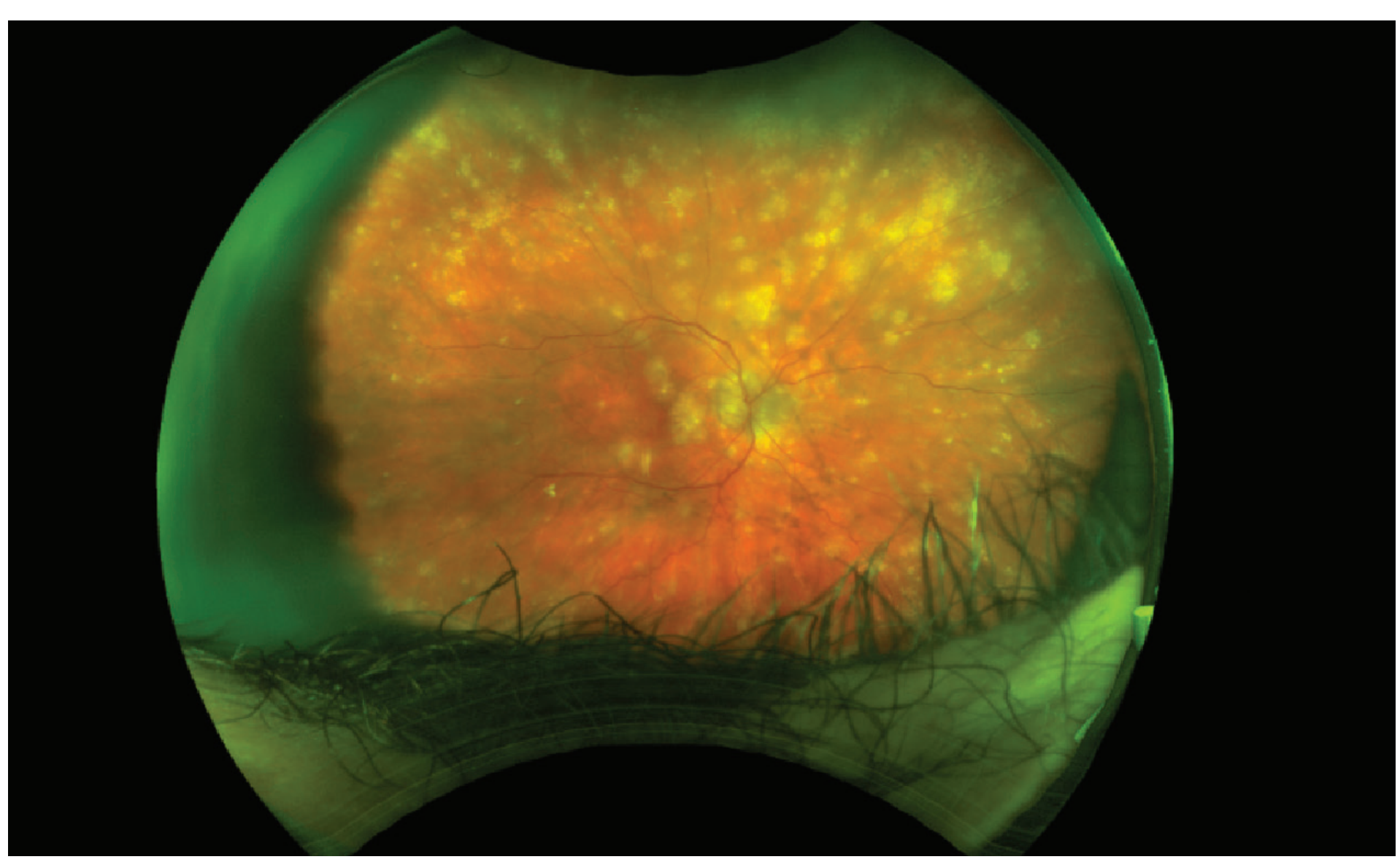

Figure 1. Mild media opacity and multifocal yellow subretinal lesions present at the initial presentation. Visual acuity was 20/20-2.

Work-up

Laboratory work-up included the following tests: syphilis immunoglobulin G and IgM, which was negative; QuantiFERON gold tuberculosis test, also negative; complete blood count (normal); and comprehensive metabolic panel (also normal). A computed tomography lung scan showed no pulmonary nodules.

Diagnosis and management

We diagnosed sympathetic ophthalmia and initiated maximum medical therapy to preserve vision in the patient's only seeing eye. That included oral prednisone 60 mg daily and methotrexate 25 mg weekly. Initially, he received adalimumab (Humira, AbbVie) every other week.

However, we eventually transitioned him to high-dose infliximab (Remicade, Janssen) because of frequent flares and an inability to fully taper the oral prednisone. We used frequent dexamethasone intravitreal injections for recurrent cystoid macular edema. Ultimately, the inflammation was brought under control (*Figure 4, page 16*).

Disease process

Sympathetic ophthalmia (SO) is a rare disease with a reported incidence of 0.1 to 0.5 percent and 19 percent after open-globe injury.[1] SO can occur after penetrating and nonpenetrating trauma, as well as intraocular surgery. Pars plana vitrectomy is reported as the most common cause of postsurgical sympathetic ophthalmia.[2–4] Presentation may be days to years after the trauma or insult, with 90 percent of cases occurring within one year.[3]

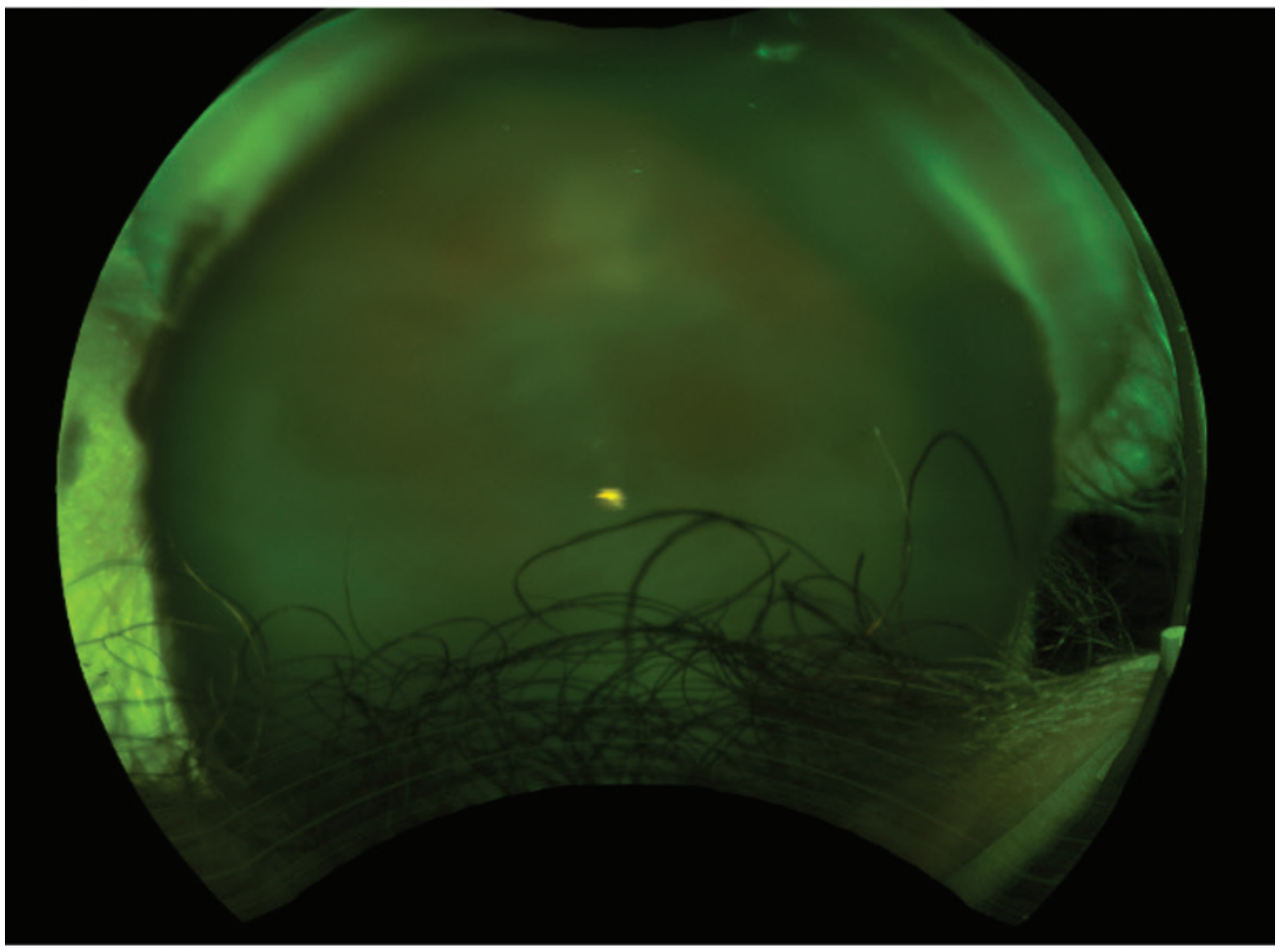

Figure 2. Dense vitreous opacities in the right eye at the initial presentation caused this poor view of the fundus findings. Visual acuity was no light perception.

Clinically SO is a bilateral granulomatous panuveitis involving any part of the uveal tract. Hallmarks of SO in the posterior segment are yellow subretinal Dalen-Fuchs nodules (clusters of epithelioid cells containing pigment lying between the RPE and Bruch's membrane), and/or multiple exudative detachments. Macular edema and choroidal neovascularization may

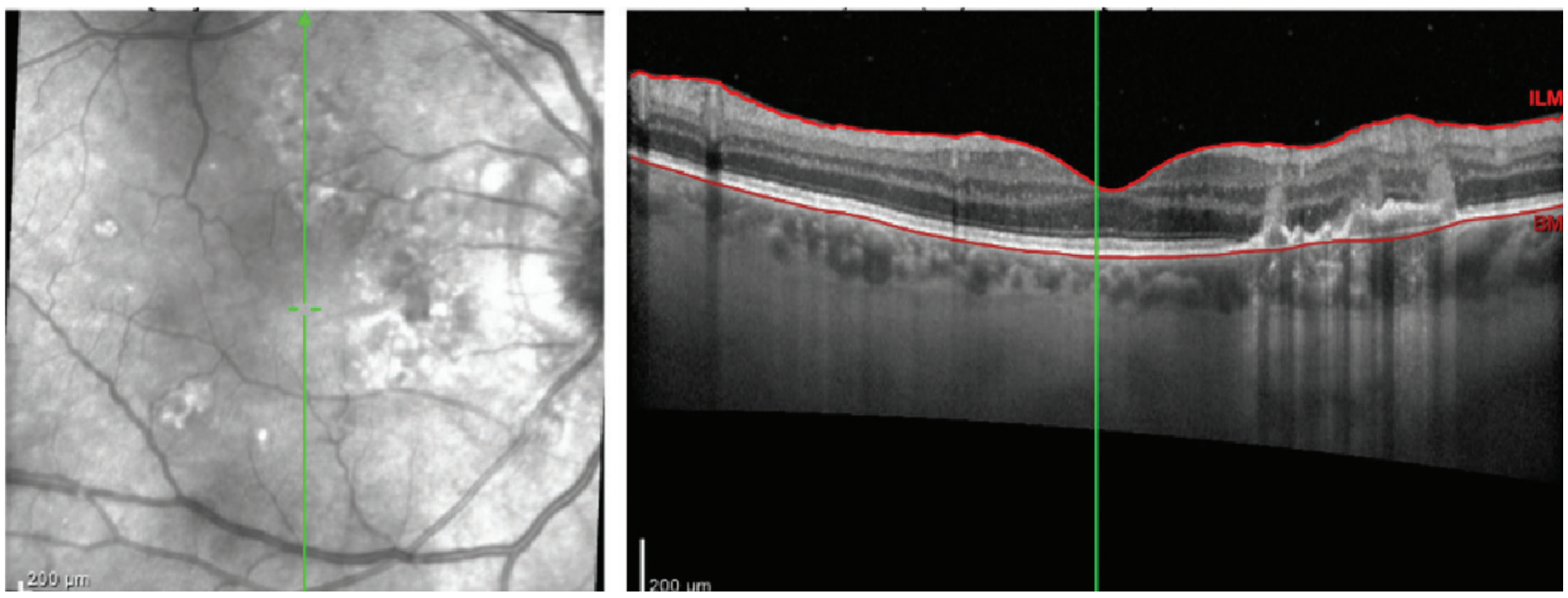

Figure 3. Optical coherence tomography imaging of the right eye at time of initial presentation shows multiple focal and confluent retinal pigment epithelium elevations in a dome shape.

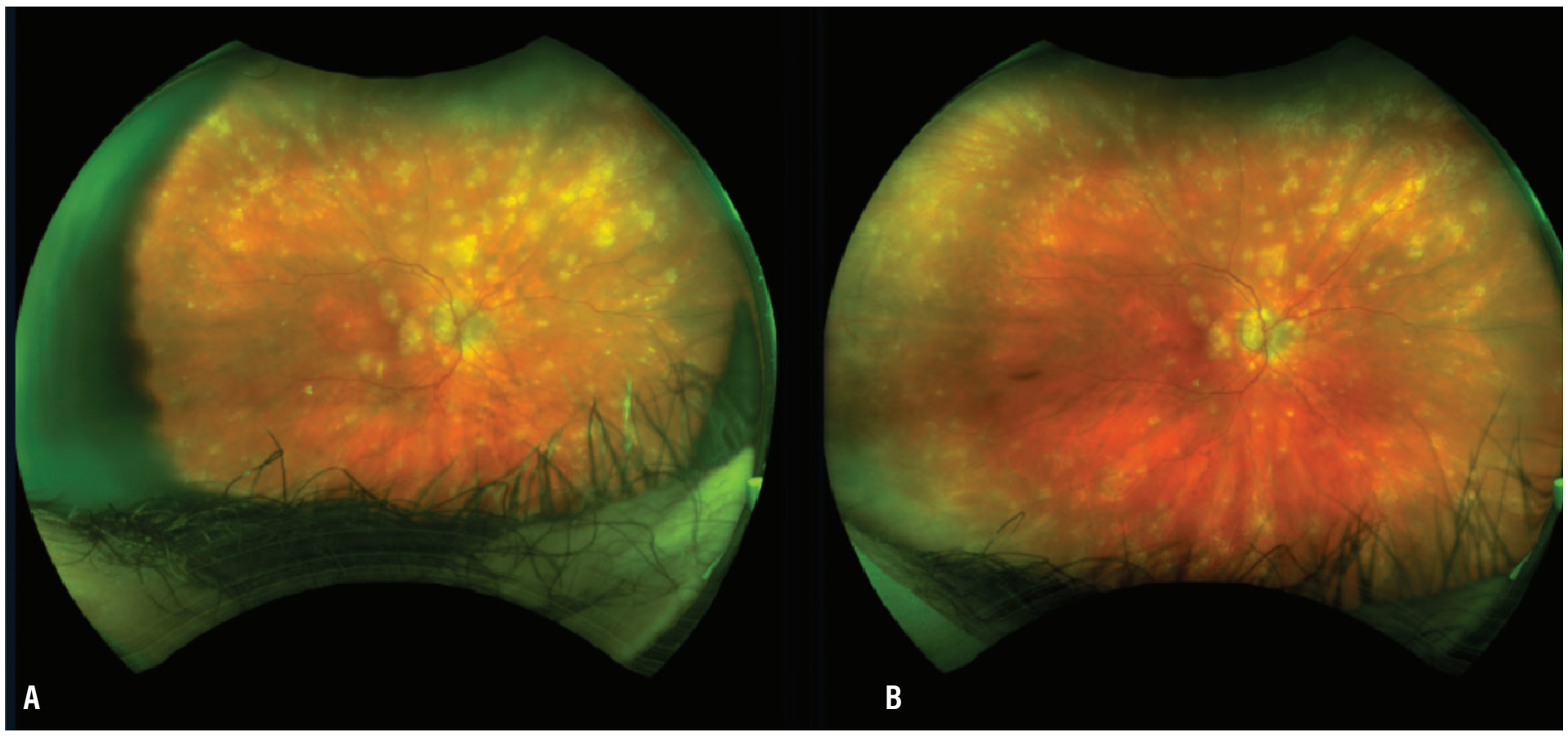

Figure 4. A) The patient's right eye at the initial presentation before starting medical therapy. B) The same eye following one year of therapy. Note the improvement in vitreous haze and decrease in subretinal yellow lesions.

complicate the disease process.[5,6]

Pathophysiology

The eye with penetrating trauma or surgery is the exciting eye and the contralateral eye is the sympathetic eye.[1–3,6] When trauma or surgery occurs, previously sequestered uveal tissue antigens become exposed to the subconjunctival space where they're presented via lymphatics to CD4+ helper T-cells in peripheral lymph nodes and the spleen.[1–6] As a result, helper CD4+ helper and CD8+ cytotoxic T-cells travel to both eyes, creating a local granulomatous immune response. Studies suggest a genetic disposition though the human leukocyte antigen, including HLA-DRB1*4 and HLA-DQB1*04[6].

Oral corticosteroids and systemic immunosuppressive agents are the first-line therapy for SO. Its severity and chronicity make it one of the few indications for which immunomodulatory therapy should be started at the initial presentation.

Treatment options

Oral corticosteroids at 1 mg/kg and systemic immunosuppressive agents are the first-line therapy for SO.[1–6] Its severity and chronicity make it one of the few indications for which immunomodulatory therapy should be started at the initial presentation.

Many cases require antimetabolites and anti-tumor necrosis factor (TNF) alpha agents for control and to prevent long-term steroid use. Anti-VEGF agents may be indicated for SO-associated choroidal neovascular membranes. Adjuvant local steroids may be used for residual inflammation or cystoid edema.[1–9]

Bottom line

Sympathetic ophthalmia is a serious, potentially sight-threatening bilateral panuveitis that follows penetrating injury or an intraocular surgery. Consider SO in cases of bilateral inflammation following PPV or open globe injury. Early treatment with immunomodulatory therapy can help control recalcitrant disease.

REFERENCES

1. Bonnie He, Stuti M. Tanya, Chao Wang, Abbas Kezouh, Nurhan Torun, Edsel Ing. The incidence of sympathetic ophthalmia after trauma: A meta-analysis. Am J Ophthalmol. 2022;234:117-125.
2. Arevalo JF, Garcia RA, Al-Dhibi HA, Sanchez JG, Suarez-Tata L. Update on sympathetic ophthalmia. Middle East Afr J Ophthalmol. 2012;19:13-21.
3. Parchand S, Agrawal D, Ayyadurai N, et al. Sympathetic ophthalmia: A comprehensive update. Indian J Ophthalmol. 2022;70:1931-1944.
4. Gass JD. Sympathetic ophthalmia following v vitrectomy. Am J Ophthalmol. 1982;93:552-558.
5. Davis JL, Mittal KK, Freidlin V, et al. HLA associations and ancestry in Vogt-Koyanagi-Harada disease and sympathetic ophthalmia. Ophthalmology. 1990;97:1137-1142.
6. Castiblanco CP, Adelman RA. Sympathetic ophthalmia. Graefes Arch Clin Exp Ophthalmol. 2009;247:289-302.
7. Galor A, Davis JL, Flynn HW, et al. Sympathetic ophthalmia: incidence of ocular complications and vision loss in the sympathizing eye. Am J Ophthalmol. 2009;148:704-710.e2.
8. Payal AR, Foster CS. Long-term drug-free remission and visual outcomes in sympathetic ophthalmia. Ocul Immunol Inflamm. 2017;25:190-195.
9. Paulbuddhe V, Addya S, Gurnani B, Singh D, Tripathy K, Chawla R. Sympathetic ophthalmia: Where do we currently stand on treatment strategies? Clin Ophthalmol. 2021;15:4201-4218.

Department Editor *Tina Felfeli, MD*

Pearls for transretinal tumor biopsy

Steps to improve your chances of performing a successful transretinal tumor biopsy.

By Ana González, MD, Hatem Krema, MD, and Filiberto Altomare, MD

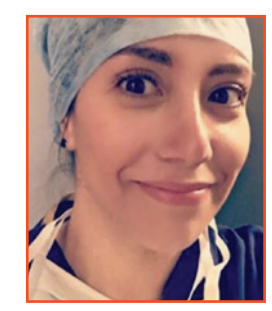
Ana González, MD


Hatem Krema, MD


Filiberto Altomare, MD

We sometimes need to perform choroidal tumor biopsy for either diagnostic or prognostic purposes, or both. With the recent advances in tumor molecular genetics, there has been a significant increase in prognostic tumor biopsies.

A variety of techniques exist for obtaining choroidal tissue depending on the size, location and accessibility of the tumor. Transretinal biopsy is recommended for posterior tumors or tumors smaller than 2 mm. This technique can be performed using indirect ophthalmoscopy or with a microscope-assisted wide-angle viewing system and chandelier illumination.[1] The latter can improve visualization, simplify the procedure and potentially result in a shorter and safer learning curve. Here, we share some tips that can increase the chances of performing a successful transretinal biopsy.

View the Video

Watch as Drs. González, Krema and Altomare share tips for choroidal mass biopsy by a transretinal approach. Available at: https://bit.ly/VideoPearl-33

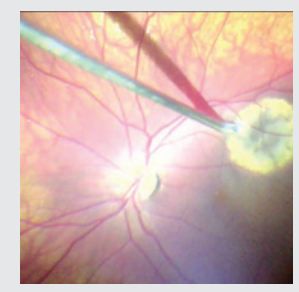

Preoperative strategies

- ***Review the key tumor measurements.*** Come to the operating room prepared

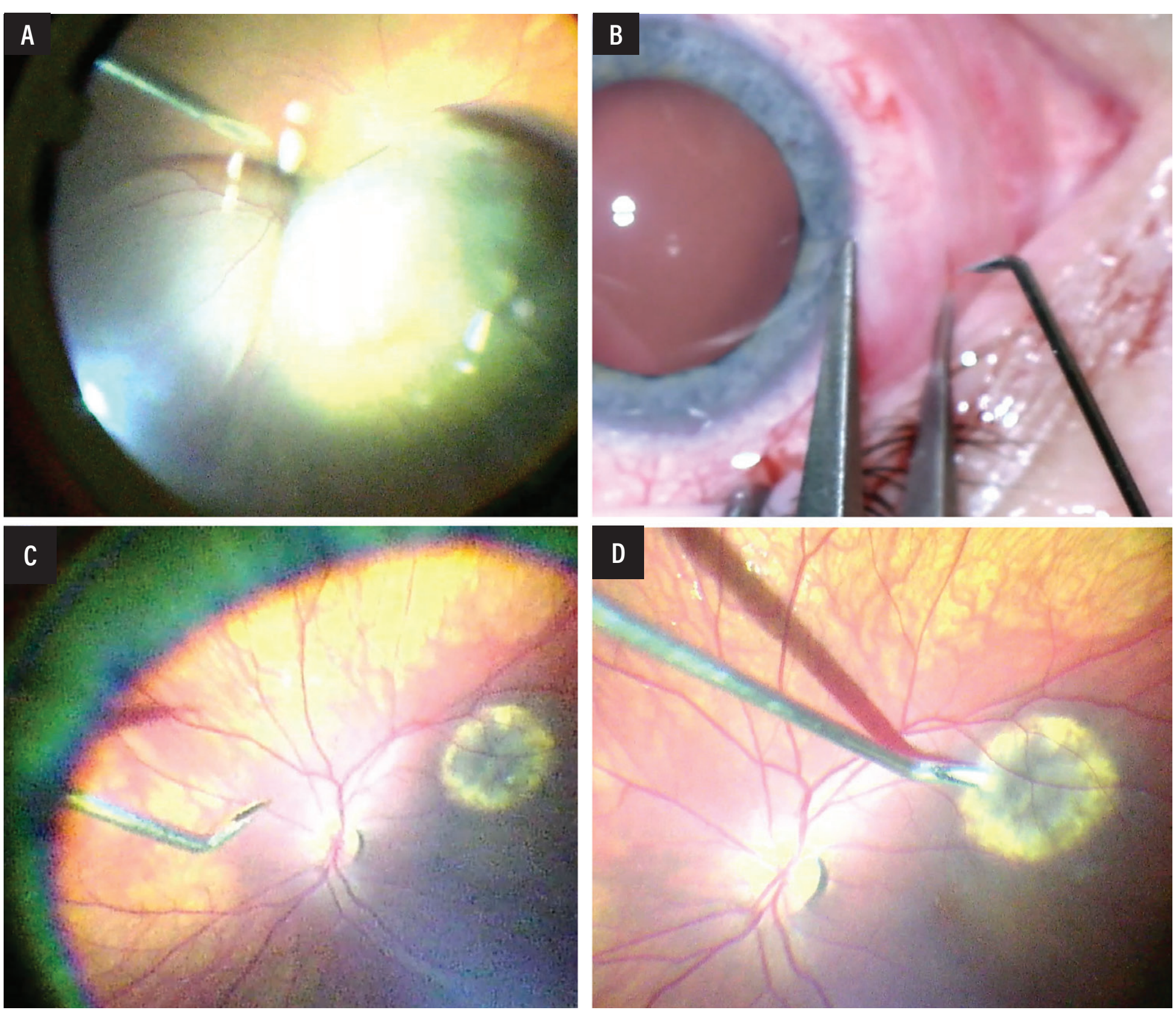

A) A straight needle enters directed toward the apex of a choroidal melanoma. B to D) The approach for a transretinal fine-needle aspiration biopsy in a tumor with a less than 2-mm thickness. In these cases, the needle is bent and a tangential incision is performed.

BIOS

Dr. González is a vitreoretinal surgeon and currently a second-year ocular oncology fellow at Princess Margaret Hospital, Toronto.

Dr. Krema is the director of the ocular oncology service at Princess Margaret Hospital and an associate professor of ophthalmology and vision sciences at the University of Toronto.

Dr. Altomare is a vitreoretinal surgeon and assistant professor of ophthalmology and vision sciences at the University of Toronto.

Dr. Felfeli is an ophthalmology resident at the University of Toronto.

DISCLOSURES: Author disclosures were not provided by presstime.

Dr. Felfeli has no relevant disclosures.

with a diagram of the tumor and its overall dimensions.

- ***Know your element.*** Verify in advance the media most appropriate for the tissue sample and whether you should contact a cytology team member for specimen collection.

Intraoperative strategies

- ***Lights on.*** Identify an appropriate clock hour for chandelier placement to maximize illumination.
- ***Needle entry.*** Under the microscope, identify the biopsy site and determine the approach angle. In our experience, an approach that's opposite the biopsy target works best. After passing through the retina into the tumor, a gentle back-and-forth motion will help to dislodge more tumor cells.
- ***Aspiration.*** Stop suction before withdrawing the needle from the tumor.
- ***Needle exit.*** Steady the needle while exiting the tumor as the sharp side of the needle can cut into the retina.
- ***Don't panic.*** Hemorrhage can occur in some cases, but it's commonly self-limiting. Raising the intraocular pressure with a cotton-tip applicator may be helpful in controlling the hemorrhage.
- ***Finishing touches.*** Once you withdraw the needle through the sclera, use a cotton-tip applicator and directly apply pressure followed by cryotherapy at the exit site.

Becoming familiar with the different types of biopsy techniques will improve the chances of safely obtaining an adequate sample for testing. RS

REFERENCE

1. Venkatesh P, Kashyap S, Temkar S, Gogia V, Garg G, Bafna RK. Endoillumination (chandelier) and wide-angle viewing-assisted fine-needle aspiration biopsy of intraocular mass lesions. Indian J Ophthalmol. 2018;66:845-847.

AI for the VR surgeon

(Continued from page 13)

classify and segment instruments and tissues in real time, which may allow for prevention of surgical errors in the future.[21] This kind of technology is a step toward making microsurgeries much safer and more precise.

Additionally, researchers at Purdue University described the AI-Medic, an AI mentor for trauma surgery that envisions autonomous medical mentoring by using computer vision and AI algorithms to provide instructions to surgeons when a reliable communication medium with an expert isn't available.[22]

Similar computer vision technology may be used in the future to evaluate a vitreoretinal surgeon's performance and to provide feedback on their technique.[23]

AI may also be used to track surgical instruments during operations.[24] This could have interesting applications for optimizing workflow in vitreoretinal surgeries. For example, AI may be able to predict which piece of equipment will be required in the next step of a surgery and aid in providing it in a timely manner. AI may also be used to ensure that certain steps aren't omitted during a procedure.

Bottom line

Many exciting applications of AI for vitreoretinal surgeons are already here and on the horizon. We agree with ChatGPT's statement: "AI has the potential to greatly enhance the practice of vitreoretinal surgery by improving surgical outcomes, increasing efficiency, and reducing the risk of complications."

However, a key consideration will be how we implement this technology in an equitable manner to ensure that it's available for all patients, including disadvantaged populations. RS

REFERENCES

1. Raman R, Dasgupta D, Ramasamy K, George R, Mohan V, Ting D. Using artificial intelligence for diabetic retinopathy screening: Policy implications. Indian J Ophthalmol. 2021;69:2993–2998.
2. Gulshan V, Rajan RP, Widner K, et al. Performance of a deep-learning algorithm vs manual grading for detecting diabetic retinopathy in India. JAMA Ophthalmol. 2019;137:987–993.
3. Xie Y, Nguyen QD, Hamzah H, et al. Artificial intelligence for teleophthalmology-based diabetic retinopathy screening in a national programme: an economic analysis modelling study. Lancet Digit Health. 2020;2:e240–249.
4. Lee CS, Baughman DM, Lee AY. Deep learning is effective for the classification of OCT images of normal versus age-related macular degeneration. Ophthalmol Retina. 2017;1:322–327.
5. Holz FG, Abreu-Gonzalez R, Bandello F, et al. Does real-time artificial intelligence-based visual pathology enhancement of three-dimensional optical coherence tomography scans optimise treatment decision in patients with nAMD? Rationale and design of the RAZORBILL study. Br J Ophthalmol. 2023;107:96–101.
6. Bogunovic H, Waldstein SM, Schlegl T, et al. Prediction of anti-VEGF treatment requirements in neovascular AMD using a machine learning approach. Invest Ophthalmol Vis Sci. 2017;58:3240–3248.
7. Bogunovic H, Abramoff M, Zhang L, Sonka M. Prediction of treatment response from retinal OCT in patients with exudative age-related macular degeneration. Ophthalmic Medical Image Analysis International Workshop 1(2014), 129-136. doi: https://doi.org/10.17077/omia.1018
8. Gupta R, Srivastava D, Sahu M, Tiwari S, Ambasta RK, Kumar P. Artificial intelligence to deep learning: machine intelligence approach for drug discovery. Mol Divers. 2021;25:1315–1360.
9. Nezu N, Usui Y, Saito A, et al. Machine learning approach for intraocular disease prediction based on aqueous humor immune mediator profiles. Ophthalmology. 2021;128:1197–1208.
10. Pucchio A, Krance SH, Pur DR, Miranda RN, Felfeli T. Artificial intelligence analysis of biofluid markers in age-related macular degeneration: A systematic review. Clin Ophthalmol. 2022;16:2463–2476.
11. Ho AC, Heier JS, Holekamp NM, Garfinkel RA, Ladd B, Awh CC, et al. Real-world performance of a self-operated home monitoring system for early detection of neovascular age-related macular degeneration. J Clin Med. 2021;10:1355.
12. Brucker AJ, AREDS II -HOME STUDY. The Home Monitoring of the Eye (HOME) study: Potential implication of findings on management of intermediate AMD patients. Invest Ophthalmol Vis Sci. 2014 ;55:3067.
13. Chen D, Yu Y, Zhou Y, et al. A deep learning model for screening multiple abnormal findings in ophthalmic ultrasonography (with video). Translational Vis Sci Tecj. 2021;10:22.
14. Fung THM, John NCRA, Guillemaut JY, et al. Artificial intelligence using deep learning to predict the anatomical outcome of rhegmatogenous retinal detachment surgery: A pilot study. Graefes Arch Clin Exp Ophthalmol. Published online October 28, 2022. Available at: https://doi.org/10.1007/s00417-022-05884-3
15. Li Z, Guo C, Nie D, et al. Deep learning for detecting retinal detachment and discerning macular status using ultra-widefield fundus images. Commun Biol. 2020;3:1–10.
16. Hu Y, Xiao Y, Quan W, et al. A multi-center study of prediction of macular hole status after vitrectomy and internal limiting membrane peeling by a deep learning model. Ann Transl Med. 2021;9:51.
17. Rizzo S, Savastano A, Lenkowicz J, et al. Artificial intelligence and OCT angiography in full thickness macular hole. New developments for personalized medicine. Diagnostics (Basel). 2021;11:2319.
18. Shao E, Liu C, Wang L, et al. Artificial intelligence-based detection of epimacular membrane from color fundus photographs. Sci Rep. 2021;11:19291.
19. Crincoli E, Savastano MC, Savastano A, et al. New artificial intelligence analysis for prediction of long-term visual improvement after epiretinal membrane surgery. Retina. 2024:43:173-181.
20. Gerber MJ, Hubschman JP. Robotics in vitreoretinal surgeries. In: Jain A, Natarajan S, Saxena S, eds. Cutting-edge Vitreoretinal Surgery. Singapore: Springer Singapore. 2021: 89–99.
21. Nespolo RG, Yi D, Cole E, Wang D, Warren A, Leiderman YI. Feature tracking and segmentation in real time via deep learning in vitreoretinal surgery-a platform for artificial intelligence-mediated surgical guidance. Ophthalmol Retina. Published online October 12, 2022. Available at: https://www.sciencedirect.com/science/article/abs/pii/S2468653022004882?via%3Dihub
22. Rojas-Muñoz E, Couperus K, Wachs JP. The AI-Medic: An artificial intelligent mentor for trauma surgery. Comput Methods Biomech Biomed Eng: Imaging Visualization. 2021;9:313–321.
23. Bakshi SK, Lin SR, Ting DSW, Chiang MF, Chodosh J. The era of artificial intelligence and virtual reality: transforming surgical education in ophthalmology. Br J Ophthalmol. 2021;105:1325–1328.
24. Nema S, Vachhani L. Surgical instrument detection and tracking technologies: Automating dataset labeling for surgical skill assessment. Frontiers Robotics AI. 2022;9:1030846.

WET AMD EYE

ANTI-VEGF

Therapy yields better long-term VA results when wet AMD detected with good VA[1]

FELLOW EYE

20/79 VA

Mean VA of fellow eyes at wet AMD diagnosis according to real-world data[1]

Over 60% of wet AMD “fellow eyes” lose too much vision[1]– even with frequent treatment visits

Detect Early. Treat Early.

ForeseeHome is a **remote monitoring** program for at-risk wet AMD fellow eyes that helps **detect conversion** at 20/40 or better in 83% of patients.[2]

- FDA Cleared
- Medicare Covered

ForeseeHOME™
AMD Monitoring Program

Introduce your patients to ForeseeHome during an injection visit and offer them an extra level of protection.

Our Monitoring Center works with your staff to easily implement an “inject and protect” protocol into your practice workflow that requires minimal effort or additional time.

The Key to Successful Home Monitoring

NOTAL VISION MONITORING CENTER

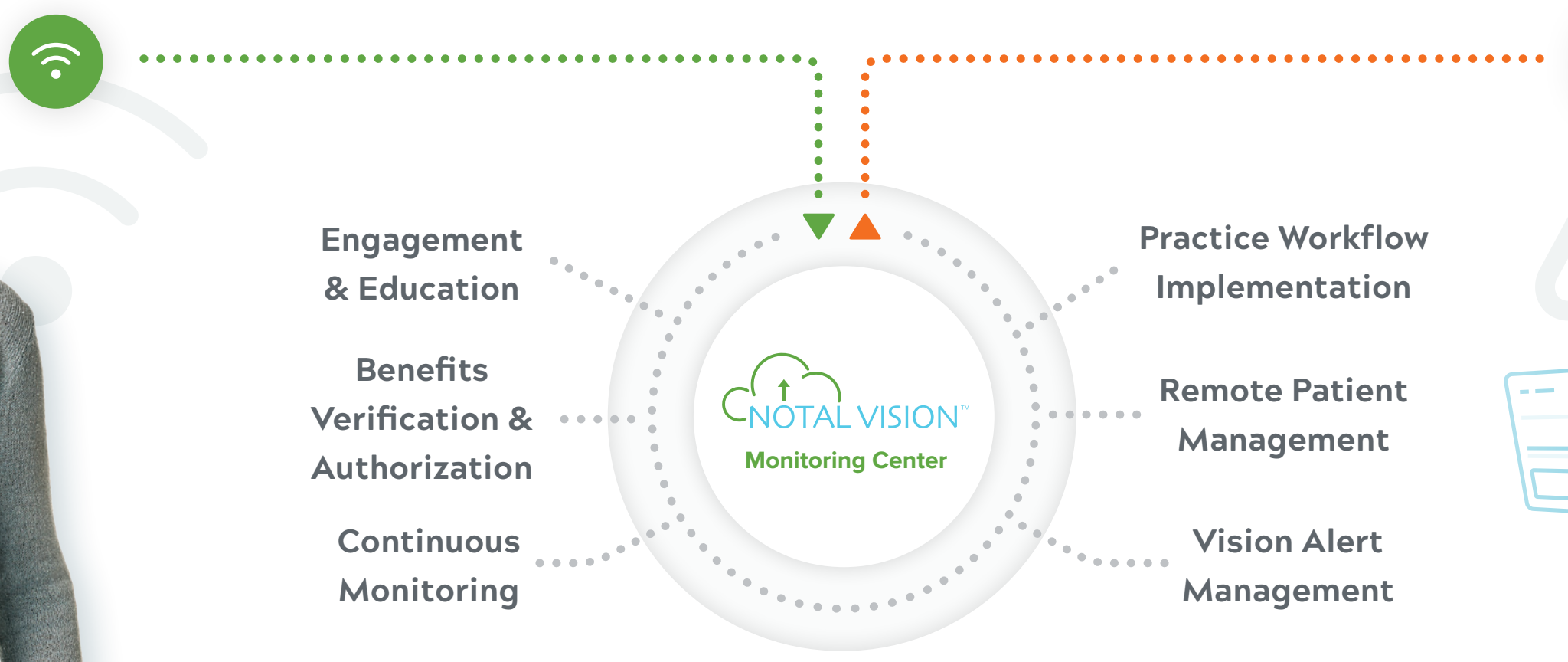

References: 1. Ho AC, Kleinman DM, Lum FC, et al. Baseline Visual Acuity at Wet AMD Diagnosis Predicts Long-Term Vision Outcomes: An Analysis of the IRIS Registry. *Ophthalmic Surg Lasers Imaging Retina*. 2020;51:633-639. **2.** Real-World Performance of a Self-Operated Home Monitoring System for Early Detection of Neovascular AMD (ForeseeHome device), presented by Allen Ho, American Society of Retina Specialist Meeting 2020.

See website for FDA Indication for Use.

SM-125.3

GET STARTED TODAY

1-855-600-3112

Mon-Fri, 8 AM to 6 PM EST

notalvision.info/retspec

The ocular side effects of emerging oncology meds

A review of how a variety of immunotherapy and targeted therapies for cancer can impact the retina and the rest of the eye.

By Basil K. Williams Jr., MD, and Soraiya Thura, MD

Basil K. Williams Jr., MD

Soraiya Thura, MD

Take-home points

- Treatments for a wide variety of cancers include immunotherapy and targeted therapies that have improved tumor control and patient survival compared with traditional chemotherapy.
- As these novel treatments became more widely used, so too did reports of ocular side effects that can range from mild and treatable to severe and sight-threatening.
- Many of these side effects can be managed while the patient continues with their cancer treatment, although in some cases the medication may need to be halted to preserve vision.
- The ophthalmologist needs to communicate with the oncologist and other specialists to ensure optimal clinical outcomes in these patients.

The development and widespread use of new approaches to treat cancer, including immunotherapy and targeted therapies, has altered the landscape of cancer treatment to provide novel ways to improve tumor control and patient survival. Targeted cancer therapies inhibit the growth and spread of cancer by impeding the action of specific molecules that promote carcinogenesis, while immunotherapy helps the immune system better identify, attack and kill cancer cells. These approaches differ from the mechanism of traditional chemotherapeutic agents that kill all rapidly dividing cells.[1,2]

As clinicians embrace and employ these novel immunotherapies, targeted therapies and chemotherapy agents, distinct potential adverse events emerge. Ocular side effects of these medications can range from extremely rare to very common, and from mild and reversible to severe and irreversible, depending on the drug.

Here, we'll outline a few of the emerging immunotherapies, chemotherapies and targeted therapies and discuss some of their known potential manifestations of ocular toxicity (*Table*).

IMMUNOTHERAPY AGENTS

Checkpoint inhibitors

The mechanism of immune checkpoint inhibitor medications is to act on proteins that regulate T-cell activity. Inhibition of these proteins allows T-cells to become activated, resulting in an immune response to help fight metastatic cancers.

The proteins inhibited by this class include cytotoxic T-lymphocyte antigen-4 (CTLA-4), programmed death protein 1 (PD-1) and programmed death ligand (PD-L1).[2,3] Some of the checkpoint inhibitors approved by the Food and Drug Administration include pembrolizumab (Keytruda, Merck), ipilimumab (Yervoy, Bristol Myers Squibb), nivolumab (Opdivo, Bristol Myers Squibb), atezolizum-

BIOS

Dr. Thura is an ocular oncology fellow at Bascom Palmer Eye Institute, University of Miami.

Dr. Williams is an associate professor of ophthalmology at the Bascom Palmer Eye Institute, where he specializes in ocular oncology and vitreoretinal diseases and surgery.

DISCLOSURES: Dr. Thura has no relevant disclosures.

Dr. Williams is a consultant for AbbVie, Castle Biosciences, EyePoint Pharmaceuticals, Genentech/Roche and Regeneron Pharmaceuticals.

ab (Tecentriq, Genentech/Roche), avelumab (Bavencio, EMD Serono/Pfizer) and durvalumab (Imfinzi, AstraZeneca). These medications are most commonly used to treat metastatic melanoma, nonsmall cell lung cancer, colon cancer, gastric cancer, head and neck squamous cell carcinoma and Hodgkin's lymphoma.[3,4]

• ***Ocular side effects.*** The ocular side effects are generally immune-related and have been reported to occur in around 1 percent of patients weeks to months after treatment starts. The most common are dry eye, conjunctivitis, episcleritis, inflammatory uveitis, exposure keratopathy, and orbital inflammation (Graves-like orbitopathy), particularly noted with the CTLA-4 inhibitor ipilimumab.[5]

Ipilimumab has also been rarely associated with aggressive bilateral uveitis similar to the exudative retinal detachments seen in Vogt-Koyanagi-Harada syndrome.[6]

With anti-PD-1 and PD-L1 agents such as pembrolizumab and nivolumab, uveitis is a rare event but requires attention for appropriate management when it does occur (*Figure 1, page 22*).[4,7] Uveitis has been noted at a rate of 0.3 to 6 percent in patients treated with checkpoint inhibitors,[8] and it sometimes requires topical or oral corticosteroids to prevent permanent visual loss.

Concerns for potential autoimmune disease, such as myasthenia gravis and thyroid disease, and worsening of paraneoplastic syndromes should be considered while patients are on checkpoint inhibitor therapy.[9]

Ocular side effects of anti-cancer therapies

Category/agent (brand name)	Oncologic indications	Ocular side effects
IMMUNOTHERAPY AGENTS		
Checkpoint inhibitors • Pembrolizumab (Keytruda, Merck) • Ipilimumab (Yervoy, Bristol Myers Squibb) • Nivolumab (Opdivo, Bristol Myers Squibb) • Atezolizumab (Tecentriq, Genentech/Roche) • Avelumab (Bavencio, EMD Serono/Pfizer) • Durvalumab (Imfinzi, AstraZeneca)	• Metastatic melanoma • Nonsmall cell lung cancer • Colon and gastric cancer • Head and neck squamous cell carcinoma • Hodgkin's lymphoma	• Dry eye • Conjunctivitis • Episcleritis • Inflammatory uveitis • Exposure keratopathy • Graves-like orbitopathy • Aggressive bilateral uveitis (ipilimumab)
Mitogen-activated protein kinase (MEK) inhibitors • Binimetinib (Mektovi, Pfizer) • Selumetinib (Koselugo, Alexion/AstraZeneca) • Cobimetinib (Cotellic, Genentech/Roche) • Trametinib (Menkinist, Novartis)	• Metastatic melanoma (can be used in combination with BRAF inhibitors, see below)	• MEK inhibitor-associated retinopathy • Retinal vein occlusion
BRAF inhibitors • Dabrafenib (Tafiniar, Novartis) • Encorafenib (Braftovi, Pfizer) • Vemurafenib (Zelboraf, Genentech/Roche)	• $BRAF^{V600}$-mutant advanced melanoma	• Dry eye • Conjunctivitis • Uveitis/panuveitis • Central serous chorioretinopathy • Squamous cell carcinoma and keratoacanthomas • Multifocal choroiditis (dabrafenib-trametinib combination) • Bilateral choroidal neovascularization (dabrafenib-trametinib combination)
ANTINEOPLASTIC AGENTS		
Taxanes • Paclitaxel • Docetaxel • Cabazitaxel (Jevtana, Sanofi/Genzyme)	• Ovarian cancer • Breast cancer • Nonsmall cell lung cancer • Gastric cancers	• Epiphora • Lacrimal duct obstruction • Dye eye • Cystoid macular edema (rare)
Methotrexate	• Breast cancer • Osteogenic carcinoma • Acute leukemia • Non-Hodgkin's lymphoma • Intraocular lymphoma	• Ocular surface toxicity • Toxic posterior optic neuropathy (rare)
Platinum analogs • Cisplatin • Carboplatin	• Solid malignancies, including of the head, neck, lungs, ovaries and testicles	• Cone dysfunction • Ischemic retinopathy • Optic nerve edema • Macular edema • Optic neuritis (high-dose or cumulative cisplatin)

MEK inhibitors

Mitogen-activated protein kinase inhibitors target the MAP kinase pathway, aberrations in which are involved in some cancers, such as metastatic melanoma.[10] The combination of BRAF (discussed later) and MEK inhibitor therapy was created for treatment of patients with unresectable or metastatic BRAF-mutated melanoma.

MEK inhibitors include the medications binimetinib (Mektovi, Pfizer), selumetinib (Koselugo, Alexion/AstraZeneca), cobimetinib (Cotellic, Genentech/Roche) and trametinib (Mekinist, Novartis), which target different stages of the signaling pathway.

• ***Ocular side effects.*** MEK inhibitor-associated retinopathy (MEKAR) tends to occur early in the course of treatment, usually within days to weeks of starting therapy (*Figure 1*). MEKAR is often transient and may resolve without permanent effects after discontinuation of treatment. The incidence of MEKAR has varied in the literature from 5 to 75 percent, due to the range of clinical presentations such as bilateral serous retinal detachments, macular edema and outer retinal layer disruption.[9,11]

Researchers at Memorial Sloan Kettering Cancer Center in New York assessed 25 patients receiving MEK-inhibitor treatment, 92 percent of whom developed bilateral subretinal fluid foci. They reported that MEKAR is often characterized by bilateral and multifocal pockets of subretinal fluid without increased choroidal thickness, which helps to differentiate it from central serous chorioretinopathy (CSCR).[12]

Retinal vein occlusion, although rare, is a potential side effect that has been reported in clinical trials of some MEK inhibitors, namely trametinib.[13] Vascular disease risk factors or glaucoma could predispose a patient to this type of event, which warrants evaluation by a retinal specialist.

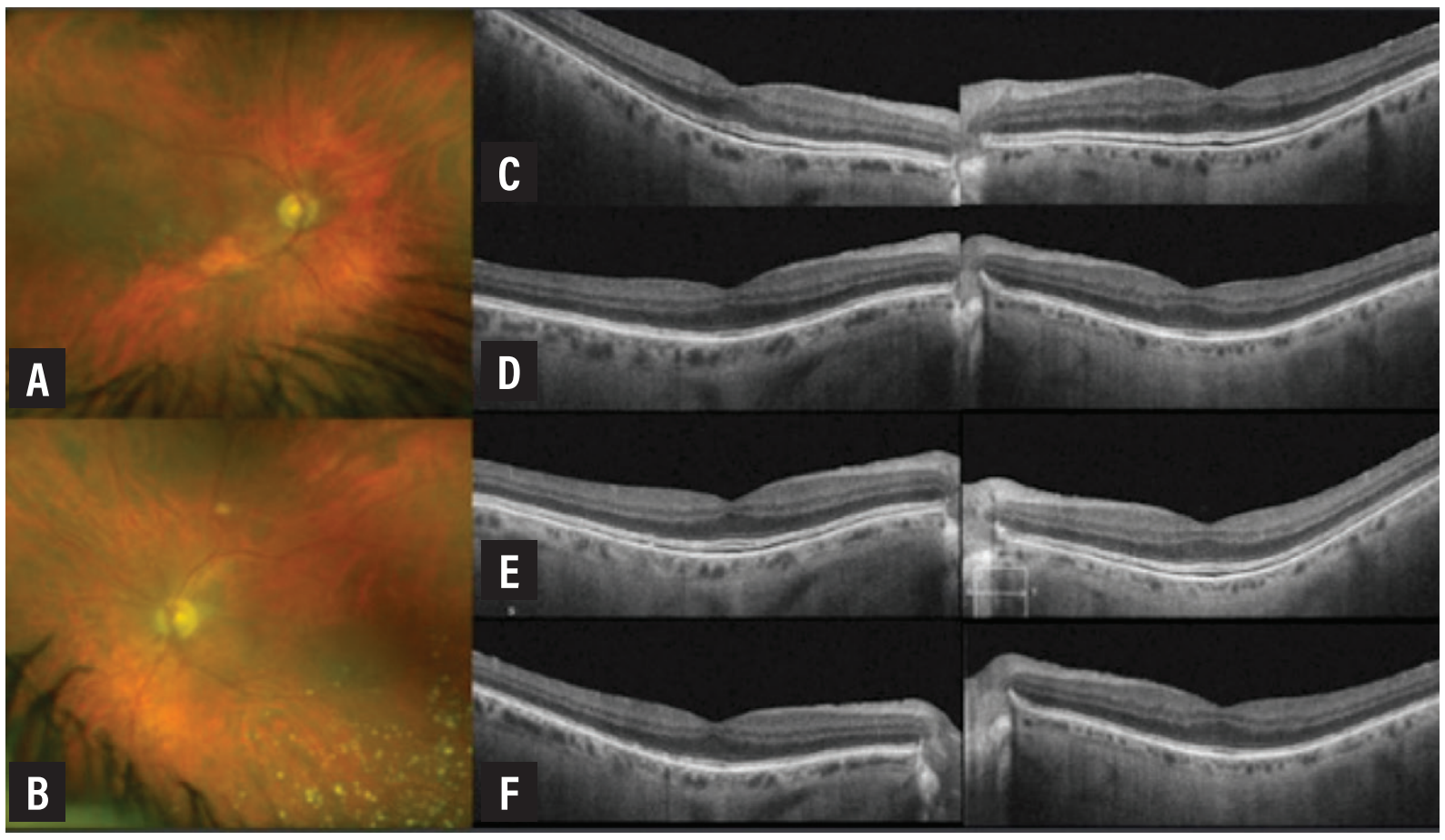

Figure 1. This asymptomatic 75-year-old male had a metastatic cutaneous melanoma treated with the MEK inhibitor binimetinib. He started on the BRAF inhibitor encorafenib two months earlier. A and B) Fundus photographs of the right and left eyes in January 2020. C) Optical coherence tomography shows subretinal fluid in both the right (left image) and the left (right image) eyes in January 2020. Best-corrected visual acuity at this point was 20/30 OD and 20/25 OS. D) OCT one month later with BCVA OD and OS 20/30. E) OCT in May 2020 with BCVA OD and OS 20/25. F) OCT in November 2020 with BCVA OD and OS 20/30.

BRAF inhibitors

BRAF inhibitors—BRAF stands for B-Raf proto-oncogene—including dabrafenib (Tafinlar, Novartis), encorafenib (Braftovi, Pfizer) and vemurafenib (Zelboraf, Genentech/Roche), which also act along the MAP kinase pathway. They're approved for the treatment of advanced cutaneous melanoma.[14]

• ***Ocular adverse events.*** OAEs that have been reported with BRAF treatment are dry eyes, conjunctivitis, uveitis, CSCR and various eyelid lesions ranging from rashes to keratoacanthomas and squamous cell carcinoma.[2,15–17] Prompt biopsy and excision of squamoproliferative eyelid lesions, which can occur with vemurafenib or dabrafenib, is recommended, but discontinuation of therapy isn't usually necessary.

The time from treatment initiation to detection of adverse events has been reported to range from a few weeks to a few months. In a large retrospective review of 568 patients who were treated with vemurafenib, 22 percent developed ocular events, the most common being uveitis, conjunctivitis and dry eye.[18]

Combination BRAF-MEKi therapy

Oncologic studies have shown that combination BRAF and MEK inhibitor therapy has additive antitumor effects, but the possibility of increased ocular toxicity in this setting remains controversial.

• ***Ocular adverse events.*** An observational pharmacovigilance study to assess OAEs with BRAF and MEK inhibitors noted a significant association between combination therapy and all types of uveitis, as well as serous retinal detachment.[14]

The combination of dabrafenib and trametinib has been reported to cause multifocal choroiditis and bilateral choroidal neovascularization.[17] Severe panuveitis may warrant discontinuing immunotherapy if local therapy or steroids don't control the inflammation.

ANTINEOPLASTIC AGENTS

Taxanes

The taxanes inhibit cancer cell proliferation through suppression of microtubule dynamics by stabilization leading to mitotic arrest.[19] This class includes paclitaxel and docetaxel, both of which have multiple brand names, and cabazitaxel (Jevtana, Sanofi/Genzyme). They're used for the treatment of ovarian cancer, breast cancer, nonsmall cell lung cancer, gastric cancers and, with cabazitaxel, advanced prostate cancer.

• ***Ocular adverse events.*** The most commonly reported OAEs include epiphora, lacrimal duct obstruction and ocular surface dryness, with the frequency of tearing noted to be as high as 88 percent while on treatment.[20] The length of treatment and cumulative dosing have been shown to relate to disease severity; the severe end of the spectrum resulting in progressive nasolacrimal duct obstruction that may warrant surgery.

A handful of case reports of cystoid macular edema have been published, although its frequency isn't well understood.[1,21] The macular edema has been described as intraretinal cystoid spaces with dome-shaped foveal configuration, nonleaking on fluorescein angiography, with spontaneous resolution after withdrawal of the taxane drug.[21]

Methotrexate

An antimetabolic, specifically a folic acid antagonist that inhibits dihydrofolate reductase, methotrexate is immunosuppressive with therapeutic activity in breast cancer, osteogenic carcinoma, acute leukemia and non-Hodgkin's lymphoma, as well as noninfectious uveitis.

• ***Ocular side effects.*** Up to a quarter of patients undergoing high-dose intravenous methotrexate therapy can develop ocular surface toxicity within the first two to seven days after starting treatment, but this is usually self-limiting and can be treated with supportive topical therapy and lubrication. The ocular surface effects can be more severe with intravitreal methotrexate injection, used in patients treated for intraocular lymphoma.

The intrathecal route of administration and long-standing low-dose methotrexate have been rarely associated with toxic posterior optic neuropathy.[9,22] The nerve damage can be reversible if the medication is discontinued early enough. Folate supplementation can help prevent this devastating complication.

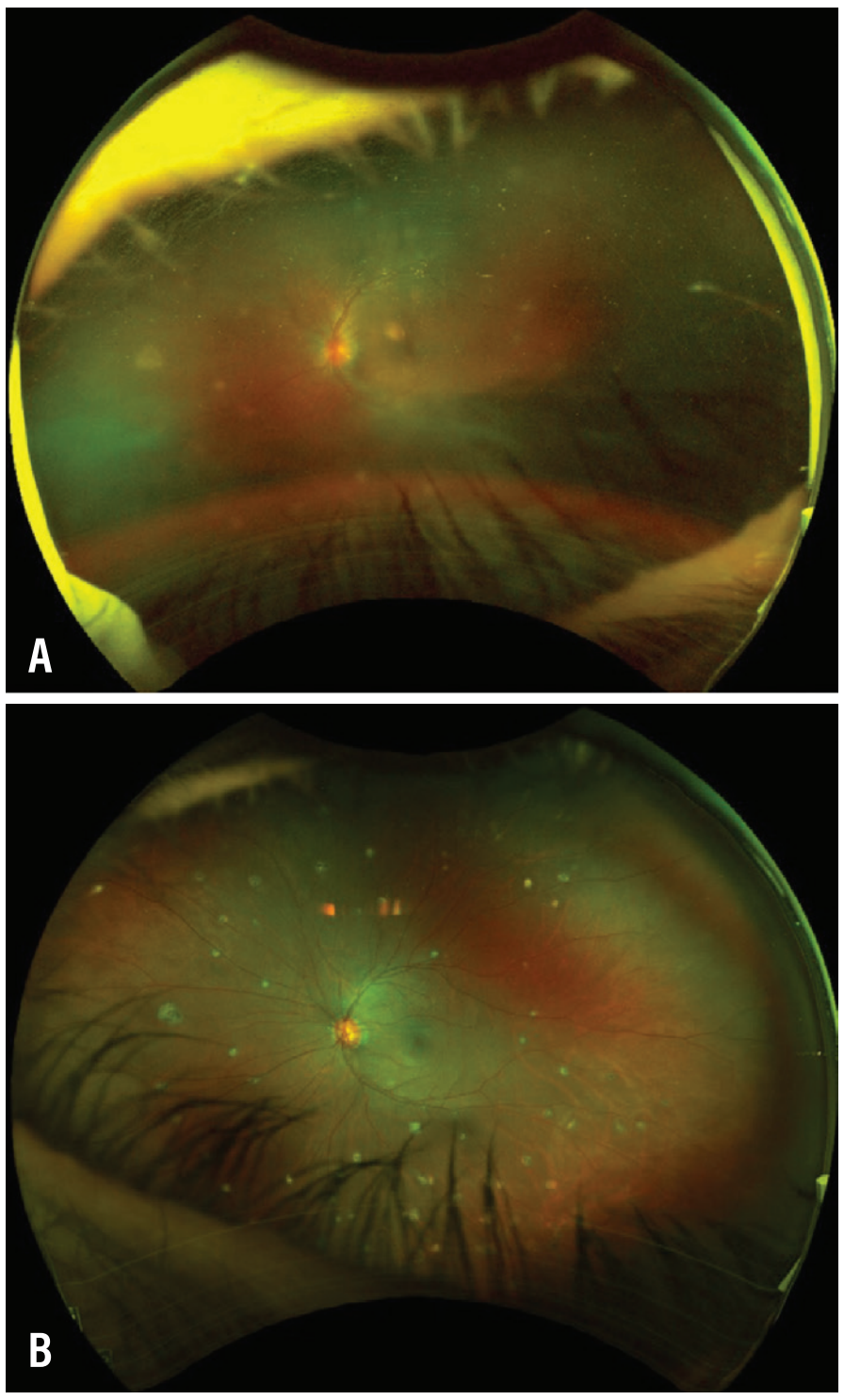

Figure 2. A) Fundus photograph of the left eye of a 35-year-old patient who developed bilateral panuveitis while on pembrolizumab, a PD-1 checkpoint inhibitor, for treatment of Hodgkin's lymphoma. Vitritis and white peripheral punctate lesions and vasculitis are notable. Best-corrected visual acuity is 20/40. B) Months after a sub-Tenon's Kenalog injection in the left eye, the vitritis improved significantly and BCVA improved to 20/20. The patient had also been taken off pembrolizumab several months earlier. The scattered peripheral lesions remain.

Platinum analogs

Cisplatin and carboplatin, both of which are available under multiple brand names, are platinum cytotoxic drugs used to treat solid malignancies, such as head and neck, lung and testicular cancers.

• ***Ocular side effects.*** Cases of retinal damage in the form of cone dysfunction, as well as ischemic retinopathy, optic nerve edema and macular edema have been reported with these medications, but they're not seen commonly.[23,24] Cisplatin has been documented to produce neurotoxicity in the form of optic neuritis that can take occur with high-dose as well as cumulative-dose regimens and macular pigmentary changes, which is one of the few irreversible ophthalmic findings.[22,25] Oncologists avoid intracarotid administration of cisplatin because of the potential for high ocular toxicity, including retrobulbar neuritis and central retinal artery occlusion.[22]

Bottom line

The wide array of novel immunotherapy and targeted therapy agents and

(Continued on page 27)

Gene therapy delivery: Examining the evidence

A look at the benefits and drawbacks of the three dominant modalities in clinical trials.

Salar Rafieetary, MD

Stephen Huddleston, MD

By Salar Rafieetary, MD, and Stephen Huddleston, MD

Take-home points

- Treatment modalities under investigation for gene therapies to treat retinal diseases include subretinal, intravitreal and suprachoroidal delivery.
- Subretinal delivery is the most used treatment option and requires pars plana vitrectomy with injection of the viral vector into the subretinal space.
- Intravitreal gene therapy is an office-based procedure, but it has limited efficacy due to long diffusion distance, dilutional effect and increased inflammatory response.
- Suprachoroidal gene therapy is also an office-based procedure, involving injection of the viral vector into the potential space between the inner sclera and outer choroid. This technique has shown promise, but more work is needed.

In 2017 voretigene neparvovec became the first retina gene therapy to receive Food and Drug Administration approval. Voretigene neparvovec is an adeno-associated virus that delivers a functional copy of the *RPE65* gene subretinally to treat Leber congenital amaurosis.

Since voretigene neparvovec (Luxturna, Spark Therapeutics) became available, active research has exploded into other modes of gene therapy delivery as well as indications beyond inherited retinal disease. Here, we will discuss different viral mechanisms for gene transduction and the different procedural techniques for administering treatment.

Most of the clinical trials involving gene therapy for IRDs are in Phase I or Phase II, with only a few trials making it to Phase III.[1] Much of our understanding of the techniques and outcomes of viral vector delivery has come from clinical trials involving gene therapy for neovascular age-related macular degeneration and diabetic macular edema, in which gene vectors, such as RGX-314 (RegenxBio), are used to upregulate gene expression of an anti-VEGF molecule.

It started with voretigene neparvovec

Voretigene neparvovec aims to treat LCA caused by *RPE65* gene mutations, which result in a deficiency of 11-cis-retinal. As a consequence, rod photoreceptors are unable to respond to light.[2] Phase III results demonstrated functional visual improvements,[3] and studies have demonstrated improved light sensitivity for up to three years, with subsequent decline.[4,5]

Subretinal delivery of the *RPE65* gene has been well-tolerated with no adverse events related to the AAV vector.[2,4,6] Humoral and cell-mediated responses to the AAV2 capsid and the *RPE65* transgene were benign in all patients, with only one patient developing a cell-mediated response to AAV.[4]

Perifoveal chorioretinal atrophy, defined

Bios

Dr. Rafieetary is a second-year retina fellow at the Charles Retina Institute in Germantown, Tennessee.

Dr. Huddleston is president of Charles Retina Institute and a clinical instructor at the University of Tennessee College of Medicine, Memphis.

DISCLOSURES: Dr. Rafieetary has no relevant disclosures.

Dr. Huddleston is researcher and paid consultant for Genentech/Roche and RegenxBio.

as progressively enlarging areas of chorioretinal atrophy not directly related to the touch-down site, has been reported in patients treated with voretigene neparvovec.[7] These changes were more commonly seen within the area of the bleb, but were also observed outside of the bleb.[8]

Viral vectors

Viral vectors for gene therapy include adenovirus, adeno-associated virus (AAV) and lentivirus. These vectors differ in their gene-carrying capacity, immunogenicity, cellular tropism and mutagenicity. AAV is the most widely used gene therapy vector.

AAV is a small, nonpathogenic virus that belongs to the Parvoviridae family. It contains a linear single-stranded DNA genome. AAV is advantageous in the use of gene delivery for many reasons, including:

- it transduces nondividing cells;
- it's less immunogenic than other virus models;
- it doesn't integrate into the host genome; and
- it maintains long-term gene expression.[9]

Because the eye is an immune-privileged site, only a limited immune reaction to the viral vector and transgene is observed.[10] AAV is safe and has demonstrated long-term gene expression in the retina.[2,4,6,11]

Intravitreal administration

Most IRDs involve genetic mutation and dysfunction at the photoreceptors and/or retinal pigment epithelium levels. Compared with subretinal administration, intravitreal injections are less effective in delivering the gene vector to the outer retina.[12] Intravitreal administration dilutes the vector in the vitreous cavity and it has to overcome a long diffusion distance to reach its target cells. Thus, higher vector concentrations are required.[9,12]

When administered intravitreally, the vector is exposed to the host's immune system, resulting in neutralizing antibodies, intraocular inflammation, and reduced clinical efficacy.[9] In animal models, subretinal administration of an AAV-RPE65 vector resulted in improved retinal function, while intravitreal administration did not.[13]

INFINITY, a Phase II trial of ADVM-022 (Ixo-vec, Adverum Biotechnologies), an AAV2 designed to deliver a transgene encoding aflibercept in patients with DME, was terminated and unmasked prematurely after a patient in the treatment arm experienced hypotony with panuveitis and vision loss.[14,15] While similar devastating adverse events haven't been reported in nAMD patients treated with ADVM-022, this adverse event has raised concern about the safety of intravitreal gene therapy.

Suprachoroidal gene therapy

The suprachoroidal space is a potential space between the inner sclera and the outer choroid. Catheters, hypodermic needles and microneedles can access this space.[16,17] Microneedles have been developed to make suprachoroidal injection an office-based procedure done with topical anesthesia.

The Phase III PEACHTREE study demonstrated efficacy of suprachoroidal

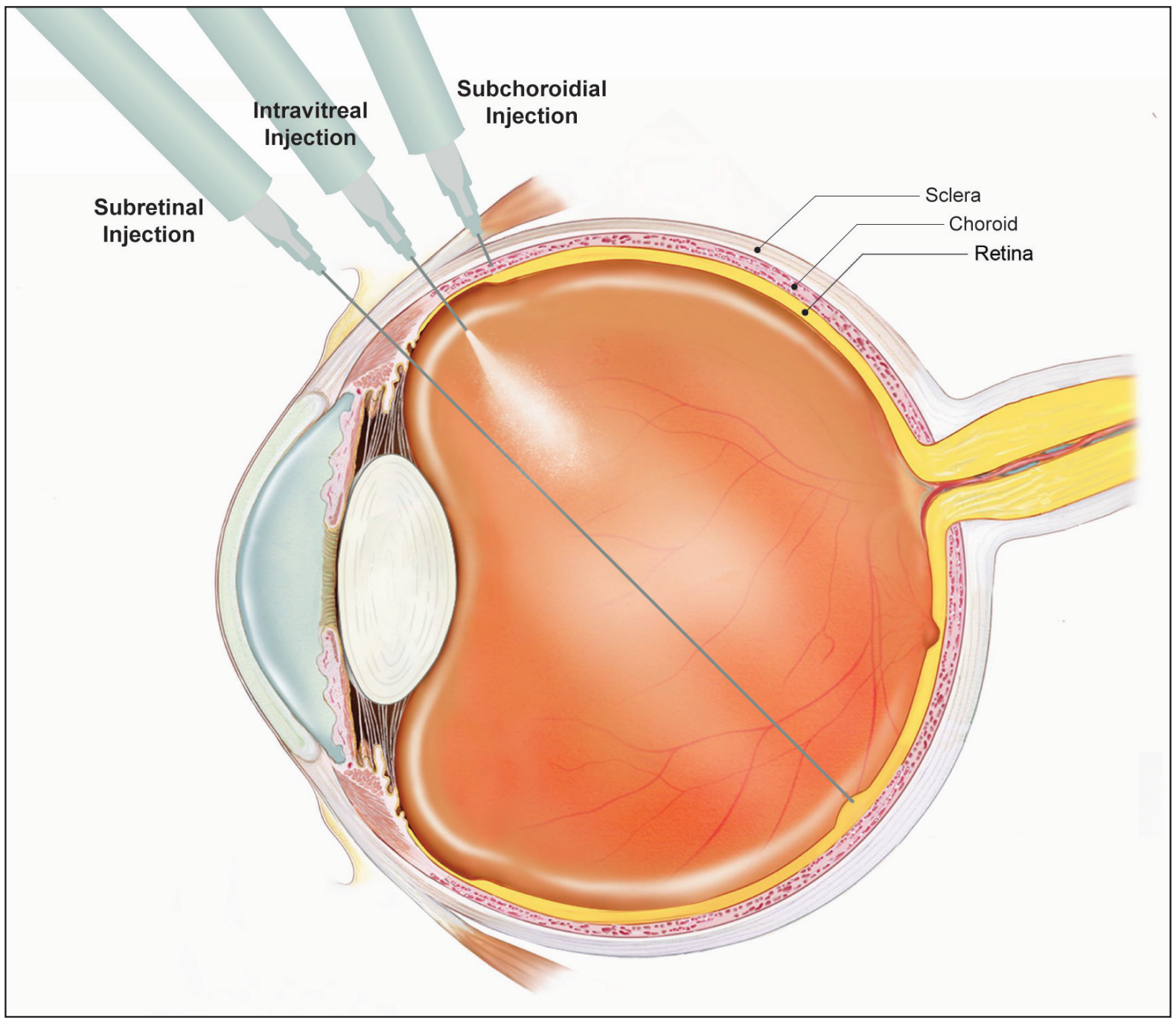

The three modalities of gene therapy delivery.

injections of triamcinolone acetonide for treatment of macular edema secondary to noninfectious uveitis.[18] Subsequently, suprachoroidal injections have been explored as a potential treatment modality for gene therapy. Compared with subretinal injections where the vector remains in high concentration in the area of the bleb, suprachoroidal gene therapy has greater spread, allowing for expression through a larger area of RPE and outer retina.[19]

Suprachoroidal gene therapy is still in the early stages of development. Despite this, encouraging results have been reported with a well-tolerated safety profile of suprachoroidal RGX-314 in nAMD.[20,21]

Subretinal delivery

Subretinal gene therapy begins with a pars plana vitrectomy and inducing a posterior vitreous detachment if one isn't already present. Triamcinolone particulate markers during this step may ensure complete hyaloid removal from the retinal surface. Hyaloidal remnants dramatically increase the overall challenge of bleb formation and agent delivery.

The vector is injected using a small-gauge cannula through the retina, creating a bleb between photoreceptors and RPE. A myriad of protocols and techniques exist for subretinal gene delivery. Many involve a pre-bleb with saline, others use the agent itself for bleb formation.

Bleb initiation may be challenging, depending on patient anatomy, patient movement and operator visualization. In many IRDs, bleb formation is a challenge because of the presence of subretinal fibrosis and excessive adhesion between the retina and RPE. Good candidates for subretinal gene therapy traditionally have clear lenses or have had cataract surgery performed by meticulous cataract surgeons, leaving minimal to no cortex. Exceeding 550 patients treated to date, the most commonly delivered subretinal gene therapy is RGX-314.

The advantage to this technique over intravitreal administration is that the subretinal space, because it is immune-privileged, has a lower likelihood of inflammation. Subretinal delivery of AAV results in gene transduction at the level of the photoreceptors, Muller cells and RPE cells.[22]

While, subretinal delivery of AAV is well tolerated, complications from the mode of administration have been reported. They include endophthalmitis, retinal detachment, macular hole and reduced visual acuity.[2,4]

Disadvantages of subretinal delivery

Disadvantages of this technique include iatrogenic separation of the retina from the RPE in bleb creation that results in photoreceptor compromise.[13] This is especially costly in patients with IRDs, where photoreceptors are at baseline abnormal. As we mentioned, perifoveal chorioretinal atrophy has been seen in certain patients after administration of voretigene neparvovec. Pigment changes without atrophy have been observed following subretinal delivery of RGX-314 as well.[14] Research into the causes is ongoing.

Another disadvantage of subretinal delivery is that it requires surgery, often with general anesthesia in pediatric patients. Other drawbacks include the lack of predictability and reproducibility with subretinal bleb formation. During bleb formation, the viral vector may extend from the injection site symmetrically in a circle or asymmetrically in one direction.[19] Viral vector may also escape into the vitreous cavity.[19]

Some immeasurable reflux out of the bleb will always occur. Blebs will also migrate before resorption, which can lead to unexpected effects such as macular transfection with superior retina bleb placement. These unpredictable surgical variables may result in variable amounts of transgene expression.[19]

Although the eye is immune-privileged, ocular inflammation almost always accompanies gene therapy regardless of the mode of delivery.

Inflammation

Although the eye is immune-privileged, ocular inflammation almost always accompanies gene therapy regardless of the delivery mode delivery.[23] Even when it's not detected clinically, histologic evidence of inflammation at the cellular level is present.

Inflammation is often responsive to immunosuppression, usually with local or systemic corticosteroids. Many variations of treatment protocols for inflammation have been reported, but no consensus exists on treatment strategies.[23]

Bottom line

Since the FDA approved voretigene neparvovec, research into gene therapies for the full spectrum of retinal diseases has expanded rapidly. Each of the three methods of administering retinal gene therapy have been evaluated, each with its own benefits and drawbacks. Inflammation is a constant concern with gene therapy administration, but the future is exciting for IRDs as well as more common conditions such as nAMD and DME.

REFERENCES

1. Nuzbrokh Y, Ragi SD, Tsang SH. Gene therapy for inherited retinal diseases. Ann Transl Med. 2021;9:1278.
2. Testa F, Maguire AM, Rossi S, et al. Three-year follow-up after unilateral subretinal delivery of adeno-associated virus in patients with Leber congenital Amaurosis type 2. Ophthalmology. 2013;120:1283-1291.
3. Maguire AM, Russell S, Wellman JA, et al. Efficacy, safety, and durability of voretigene neparvovec-rzyl in RPE65 mutation-associated inherited retinal dystrophy: Results of Phase 1 and 3 trials. Ophthalmology. 2019;126:1273-1285.
4. Bennett J, Wellman J, Marshall KA, et al. Safety and durability of effect of contralateral-eye administration of AAV2 gene therapy in patients with childhood-onset blindness caused by RPE65 mutations: a follow-on phase 1 trial. Lancet. 2016;388:661-672.
5. Jacobson SG, Cideciyan AV, Roman AJ, et al. Improvement and decline in vision with gene therapy in childhood blindness. N Engl J Med. 2015;372:1920-1926.
6. Russell S, Bennett J, Wellman JA, et al. Efficacy and safety of voretigene neparvovec (AAV2-hRPE65v2) in patients with RPE65-mediated inherited retinal dystrophy: A randomised, controlled, open-label, phase 3 trial. Lancet. 2017;390:849-860.
7. Gange WS, Sisk RA, Besirli CG, et al. Perifoveal chorioretinal atrophy after subretinal voretigene neparvovec-rzyl for RPE65-mediated Leber congenital amaurosis. Ophthalmol Retina. 2022;6:58-64.
8. Reichel FF, Seitz I, Wozar F, et al. Development of retinal atrophy after subretinal gene therapy with voretigene neparvovec. Br J Ophthalmol. Published onine May 24, 2022. Available at: https://bjo.bmj.com/content/early/2022/05/23/bjophthalmol-2021-321023.long
9. Ross M, Ofri R. The future of retinal gene therapy: evolving from subretinal to intravitreal vector delivery. Neural Regen Res. 2021;16:1751-1759.
10. Surace EM, Auricchio A. Versatility of AAV vectors for retinal gene transfer. Vision Res. 2008;48:353-359.
11. Day TP, Byrne LC, Schaffer DV, Flannery JG. Advances in AAV vector development for gene therapy in the retina. Adv Exp Med Biol. 2014;801:687-693.
12. Peng Y, Tang L, Zhou Y. Subretinal injection: A review on the novel route of therapeutic delivery for vitreoretinal diseases. Ophthalmic Res. 2017;58:217-226.
13. Acland GM, Aguirre GD, Bennett J, et al. Long-term restoration of rod and cone vision by single dose rAAV-mediated gene transfer to the retina in a canine model of childhood blindness. Mol Ther. 2005;12:1072-1082.
14. Khanani AM, Thomas MJ, Aziz AA, et al. Review of gene therapies for age-related macular degeneration. Eye (Lond). 2022;36:303-311.
15. Adverum provides update on ADVC-011 and the INFINITY trial in patients with diabetic macular edema [press release]. Redwood City, CA: Adverum Biotechnologies; July 22, 2021.
16. Kansara VS, Hancock SE, Muya LW, Ciulla TA. Suprachoroidal delivery enables targeting, localization and durability of small molecule suspensions. J Control Release. 2022;349:1045-1051.
17. Patel SR, Lin AS, Edelhauser HF, Prausnitz MR. Suprachoroidal drug delivery to the back of the eye using hollow microneedles. Pharm Res. 2011;28:166-176.
18. Yeh S, Khurana RN, Shah M, et al. Efficacy and safety of suprachoroidal CLS-TA for macular edema secondary to noninfectious uveitis: Phase 3 randomized trial. Ophthalmology. 2020;127:948-955.
19. Ding K, Shen J, Hafiz Z, et al. AAV8-vectored suprachoroidal gene transfer produces widespread ocular transgene expression. J Clin Invest. 2019;129:4901-4911.
20. Khanani AM. Suprachoroidal delivery of RGX-314 gene therapy for neovascular AMD: The Phase II AAVIATE study. Invest Ophthalmol Vis Sci. 2022;63:1497.
21. Vajzovic L. Suprachoroidal delivery of RGX-314 for diabetic retinopathy: The Phase II ALTITUDE study. Paper presented at the 55th annual Scientific Meeting of the Retina Society; Pasadena, CA; November 2, 2022.20.
22. Bennett J. Taking stock of retinal gene therapy: Looking back and moving forward. Mol Ther. 2017;25:1076-1094.
23. Chan YK, Dick AD, Hall SM, et al. Inflammation in viral vector-mediated ocular gene therapy: a review and report from a workshop hosted by the Foundation Fighting Blindness, 9/2020. Transl Vis Sci Technol. Published online April 1, 2021. Available at: https://tvst.arvojournals.org/article.aspx?articleid=2772451

Ocular side effects of emerging oncology meds

(Continued from page 23)

chemotherapy drugs that have been introduced to treat a diverse range of malignancies has been revolutionary for the field of oncology. These medications can have distinct systemic effects, but we continue to add to our knowledge of their ophthalmic adverse effects as well. Ocular changes from some of these medications include serous retinopathy, macular edema, uveitis, optic nerve edema and surface disease.

Many of these findings can be managed while the patient continues with their potentially life-saving anticancer treatment, although in vision-threatening cases, the medication may need to be discontinued. Communication and partnership between the oncologist, ophthalmologist and other specialists is vital for optimal clinical outcomes.

REFERENCES

1. Kheir WJ, Sniegowski MC, El-Sawy T, Li A, Esmaeli B. Ophthalmic complications of targeted cancer therapy and recently recognized ophthalmic complications of traditional chemotherapy. Surv Ophthalmol. 2014;59:493-502.
2. Bindiganavile SH, Bhat N, Lee AG, Gombos DS, Al-Zubidi N. Targeted cancer therapy and its ophthalmic side effects: A review. J Immunother Precis Oncol. 2021;4:6-15.
3. Wladis EJ, Kambam ML. Ophthalmic complications of immune checkpoint inhibitors. Orbit. 2022;41:28-33.
4. Dalvin LA, Shields CL, Orloff M, Sato T, Shields JA. Checkpoint inhibitor immune therapy: Systemic indications and ophthalmic side effects. Retina. 2018;38:1063-1078.
5. Dow ER, Yung M, Tsui E. Immune checkpoint inhibitor-associated uveitis: Review of treatments and outcomes. Ocul Immunol Inflamm. 2021;29:203-211.
6. Crews J, Agarwal A, Jack L, Xu D, Do DV, Nguyen QD. Ipilimumab-associated retinopathy. Ophthalmic Surg Lasers Imaging Retina. 2015;46:658-660.
7. Mukhtar S, Jhanji V. Effects of systemic targeted immunosuppressive therapy on ocular surface. Curr Opin Ophthalmol. 2022;33:311-317.
8. Abdel-Rahman O, Oweira H, Petrausch U, et al. Immune-related ocular toxicities in solid tumor patients treated with immune checkpoint inhibitors: A systematic review. Expert Rev Anticancer Ther. 2017;17:387-394.
9. Liu CY, Francis JH, Abramson DH. Ocular side effects of systemically administered chemotherapy. 2023. UpToDate. Updated January 5, 2023. Available at: https://www.uptodate.com/contents/ocular-side-effects-of-systemically-administered-chemotherapy. Accessed March 2, 2023.
10. Dhillon AS, Hagan S, Rath O, Kolch W. MAP kinase signaling pathways in cancer. Oncogene. 2007;26:3279-3290.
11. Urner-Bloch U, Urner M, Jaberg-Bentele N, Frauchiger AL, Dummer R, Goldinger SM. MEK inhibitor-associated retinopathy (MEKAR) in metastatic melanoma: Long-term ophthalmic effects. Eur J Cancer. 2016;65:130-138.
12. Francis JH, Habib LA, Abramson DH, et al. Clinical and morphologic characteristics of MEK inhibitor–associated retinopathy: Differences from central serous chorioretinopathy. Ophthalmology. 2017;124:1788-1798.
13. Infante JR, Fecher LA, Falchook GS, et al. Safety, pharmacokinetic, pharmacodynamic, and efficacy data for the oral MEK inhibitor trametinib: A phase 1 dose-escalation trial. Lancet Oncol. 2012;13:773-781.
14. Mettler C, Monnet D, Kramkimel N, et al. Ocular safety profile of BRAF and MEK inhibitors: Data from the World Health Organization Pharmacovigilance Database. Ophthalmology. 2021;128:1748-1755.
15. Yin VT, Wiraszka TA, Tetzlaff M, Curry JL, Esmaeli B. Cutaneous eyelid neoplasms as a toxicity of vemurafenib therapy. Ophthalmic Plast Reconstr Surg. 2015;31:e112-115.
16. Eikenberry J, Harris A, Torabi R, et al. Ocular side effects of target therapy and immunotherapy in patients with cutaneous malignant melanoma. Eur J Ophthalmol. 2021;31:1391-1398.
17. Albertini GC, Corbelli E, Battaglia Parodi M, Bandello F. Choroidal neovascularization in multifocal choroiditis after dabrafenib and trametinib. Eur J Ophthalmol. 2017;27:e184-e186.
18. Choe CH, McArthur GA, Caro I, Kempen JH, Amaravadi RK. Ocular toxicity in BRAF mutant cutaneous melanoma patients treated with vemurafenib. Am J Ophthalmol. 2014;158831-837.e2.
19. Azarenko O, Smiyun G, Mah J, Wilson L, Jordan MA. Antiproliferative mechanism of action of the novel taxane cabazitaxel as compared with the parent compound docetaxel in MCF7 breast cancer cells. Mol Cancer Ther. 2014;13:2092-2103.
20. Fortes BH, Liou H, Dalvin LA. Ophthalmic adverse effects of taxanes: The Mayo Clinic experience. Eur J Ophthalmol. 2022;32:602-611.
21. Ye YT, Zhou ZY, Wen LS, Sun Y, Chu ZJ, Dou GR. The significance of the ocular adverse effect induced by systemic taxane application. Front Biosci (Landmark Ed). 2022;27:171.
22. Schmid KE, Kornek G v., Scheithauer W, Binder S. Update on ocular complications of systemic cancer chemotherapy. Surv Ophthalmol. 2006;51:19-40.
23. Dulz S, Asselborn NH, Dieckmann KP, et al. Retinal toxicity after cisplatin-based chemotherapy in patients with germ cell cancer. J Cancer Res Clin Oncol. 2017;143:1319-1325.
24. Wilding G, Caruso R, Lawrence TS, et al. Retinal toxicity after high-dose cisplatin therapy. J Clin Oncol. 1985;3:1683-1689.
25. Kupersmith MJ, Seiple WH, Holopigian K, Noble K, Hiesiger E, Warren F. maculopathy caused by intra-arterially administered cisplatin and intravenously administered carmustine. Am J Ophthalmol. 1992;113:435-438.

How multimodal imaging raises the bar for RRD repair

The potential of imaging biomarkers are emerging as useful outcome measures for future trials in rhegmatogenous retinal detachment.

By Wei Wei Lee, MD, and Rajeev H. Muni, MD, FRCSC

Wei Wei Lee, MD

Rajeev H. Muni, MD, FRCSC

BIOS

Dr. Lee is a vitreoretinal surgeon at Dr. Everett Chalmers Hospital, Fredericton, New Brunswick, Canada.

Dr. Muni is a vitreoretinal surgeon at St. Michael's Hospital/ Unity Health Toronto and a vice chair of clinical research in the department of ophthalmology and vision sciences at the University of Toronto.

DISCLOSURES: Dr. Lee has no relevant disclosures.

Dr. Muni is a consultant to Alcon, Bausch + Lomb, Novartis and Roche, and receives grants or research funding from Bayer, Novartis and Roche.

Take-home points

- The definition of a successful retinal detachment repair is undergoing a significant shift from the traditional single surgery anatomic reattachment to achieving structural integrity of the retinal reattachment. In other words, it's no longer only about how often the retina is attached with a single procedure, but how well the retina is attached.
- Multimodal imaging is crucial in assessing the integrity of retinal reattachment
- Imaging biomarkers such as discontinuity of the outer retinal bands and outer retinal folds on optical coherence tomography and the presence of retinal vessel printings on fundus autofluorescence have been associated with worse functional outcomes following rhegmatogenous retinal detachment repair. These imaging biomarkers will be important in future clinical trials that will evaluate various treatments for RRD repair.

Several advances in our surgical techniques have emerged over the past century, and we are fortunate to have multiple treatment options for rhegmatogenous retinal detachment, including pneumatic retinopexy, scleral buckle and pars plana vitrectomy.

Despite the availability of these options, the debate over the best approach for RRD repair has been ongoing.[1–3] This is related in part to limited randomized trials comparing various treatment options for RRD.

However, advancements in retinal imaging technology over the years have allowed us to gather more data and to better understand the process of retinal detachment and reattachment, which may potentially assist retinal surgeons in making treatment decisions and planning future studies involving a variety of anatomic imaging biomarkers.

A change in perspective on RRD repair

Advancements in microsurgical instrumentation over the past few decades have

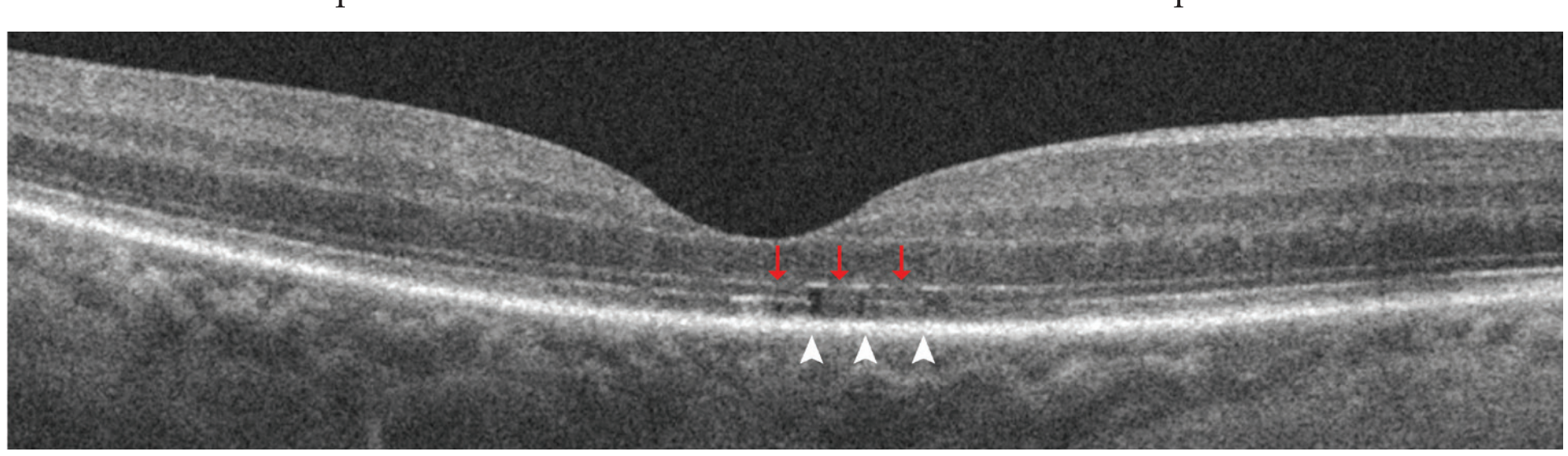

Figure 1. Representative spectral-domain optical coherence tomography five-line raster images with discontinuity of the outer retinal bands three months after macula-off detachment repair. It shows discontinuity of the external limiting membrane (red arrows) and discontinuity of ellipsoid zone and interdigitation zone (white arrowheads) in the foveal scan.

improved the single-surgery success rates of RRD repair. However, despite successful anatomic reattachment, patients may still experience suboptimal functional outcomes and complain of reduced visual acuity, metamorphopsia or aniseikonia.[4–9] This has led to a pivotal change in how we view a successful RRD repair from the traditional anatomic reattachment to achieving structural integrity of the retinal reattachment.

Several authors have discussed different approaches to repairing a RRD to achieve a high-integrity retinal attachment, highlighting the importance of reattaching the retina as closely as possible to its original location rather than reattaching the retina in a stretched state, which can result in what we refer to as a low-integrity retinal attachment.

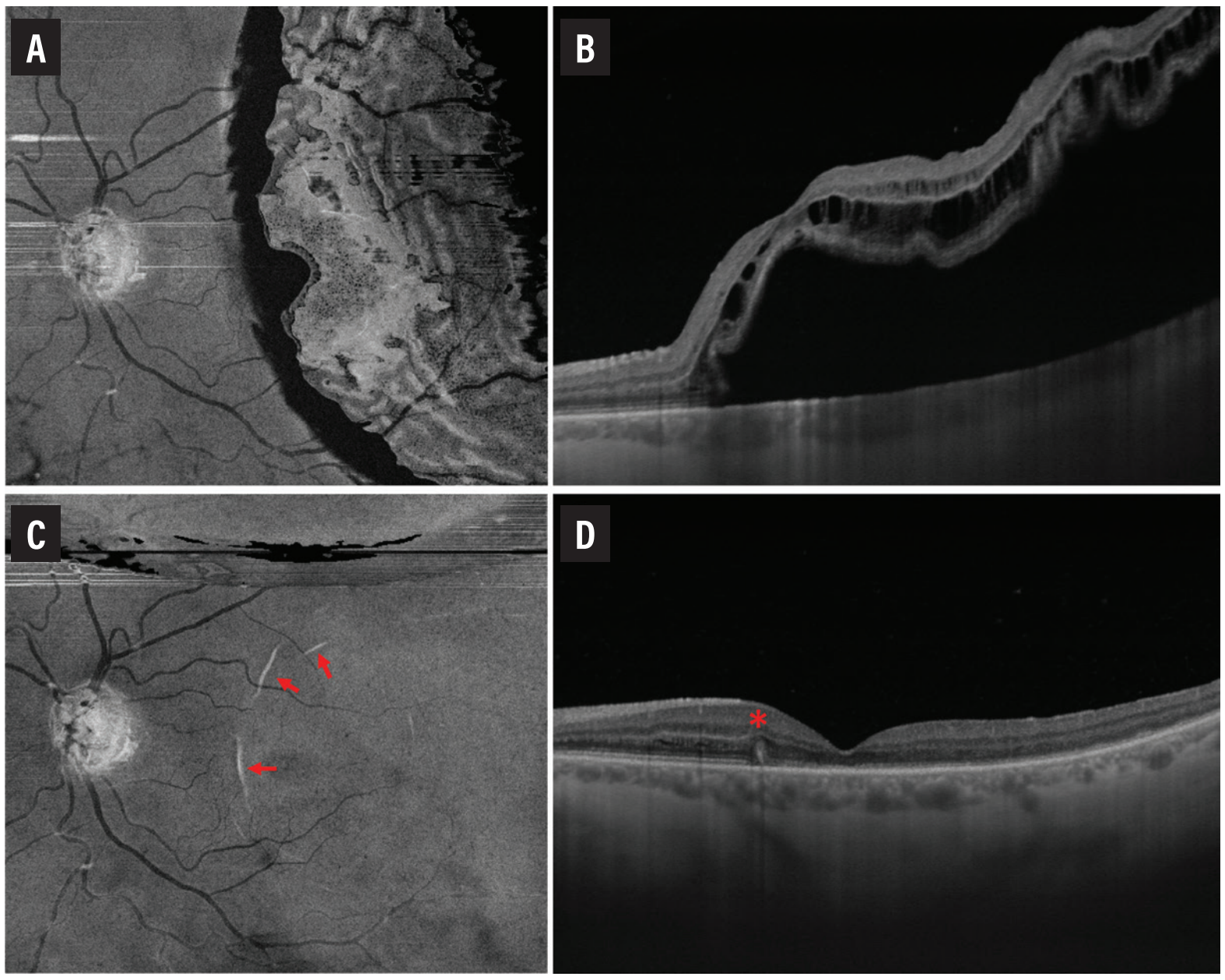

Figure 2. ***En face*** **and cross-sectional swept-source optical coherence tomography images of a patient before (A, B) and one week after (C, D) retinal detachment repair. Outer retinal folds are evidenced by the presence of hyper-reflective curvilinear lesions (red arrows) on the** ***en face*** **slab (C) with corresponding protrusions (red asterisk) on the cross-sectional (D) OCT scans of an eye that had recent RD repair.**

Functional outcome measures

Functional outcome measures after RRD repair are essential because they provide a quantitative assessment for evaluating the success of different surgical techniques and provide information regarding prognosis. Past landmark studies have mainly used visual acuity as the primary measure of functional outcome, but in recent years investigators have had increased interest in the assessment of outcomes beyond VA, such as metamorphopsia and aniseikonia.

Many studies have incorporated objective assessment of these functional outcome measures after RRD repair, using M-CHARTS (Inami & Co.) to measure the degree of metamorphopsia[5–7] and the Awaya new aniseikonia test (Handaya) for aniseikonia.[8,9] Several authors have demonstrated that the incidence of metamorphopsia after RRD repair is significant, ranging from 56.7 to 88.6 percent.[5,7,10,11] Similarly, aniseikonia has been reported in as many as 42 to 58 percent of patients post-RRD repair.[8,9]

Role of multimodal imaging

Although metamorphopsia and aniseikonia are common following RRD repair, the pathophysiological basis is still not clearly understood due to conflicting evidence in the existing literature. Many contributing factors reduce functional outcomes after RRD repair, some of which are apparent on clinical examination. They include epiretinal membrane, cystoid macula edema or macula hole, but some can't be explained by clinical examination alone.

Researchers at Tsukuba University in Japan reported that two-third of patients who had significant metamorphopsia exhibited normal macular contour with no identifiable gross abnormalities, such as ERM, CME, macular hole or persistent subretinal fluid, suggesting the existence of microstructural macular changes that standard fundus biomicroscopy couldn't detect.[7] In these cases, using multimodal imaging biomarkers has the potential to reveal important pathology that may explain the suboptimal functional outcomes.

Multimodal imaging has also given us a better understanding of the pathophysiology of RRD and its morphological stages,[12] and the process of healing during reattachment.[13]

Imaging modalities are also used to visualize and comprehend the changes that the retina undergoes with different treatment modalities (i.e., PPV vs. pneumatic retinopexy [PnR],[14] or laser retinopexy vs cryopexy[15]). Understanding these changes allows us to consider ways to improve or modify our surgical techniques to improve postoperative outcomes.

The following are the imaging modalities that can be useful in the management of RRD.

Optical coherence tomography

Several studies have used OCT to evaluate changes in the outer retina bands after RRD repair and have demonstrated the association of microstructural abnormalities with suboptimal functional outcomes.[4,14,16,17] The microstructural imaging analysis of the fovea involved assessing for discontinuity of the outer retinal bands, specifically the external limiting membrane, ellipsoid zone and the interdigitation zone (IZ) (*Figure 1, page 28*), and the presence of outer retinal folds (ORFs) (*Figure 2, page 29*).

Researchers at Osaka University in Japan reported that postoperative integrity of the ELM and EZ are significant predictors of postoperative best-corrected visual acuity.[4] Another team of Japanese researchers at Nagoya University supported these findings by demonstrating that BCVA correlated with thickness of the EZ to retinal pigment epithelium layer.[17]

Our group's post-hoc analysis of a randomized controlled trial demonstrated that presence of ORFs was associated with worse visual acuity after RRD repair.[16] Several other authors have demonstrated significant associations of metamorphopsia with outer retina abnormalities, such as ELM disruption[5,11] and IZ discontinuity.[5] Presence of aniseikonia were also associated with OCT changes. The Tsukuba University researchers in Japan demonstrated that a disrupted EZ was associated with aniseikonia.[8]

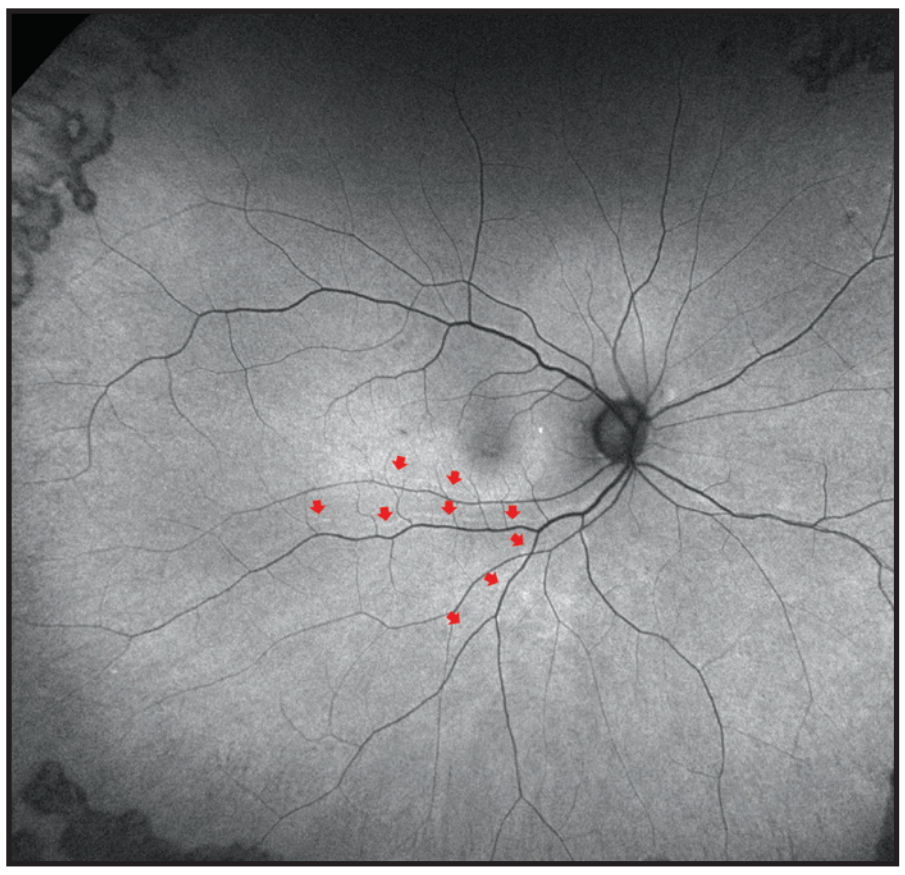

Figure 3. Fundus autofluorescence three months after retinal detachment repair demonstrates anatomic reattachment with retinal displacement as evidenced by presence of retinal vessel printings (red arrows).

OCT angiography

OCT-A is a noninvasive way to both qualitatively and quantitatively assess the retinal vasculature following RRD repair. By enabling visualization of the superficial and deep capillary plexus (SCP and DCP), OCT-A also facilitates measurement of the foveal avascular zone (FAZ) size. Previous studies have shown that patients who undergo RRD repair exhibit FAZ enlargement at both the SCP and DCP compared to their contralateral normal eye.

Additionally, patients with macula-off RRD tend to have a larger FAZ than those with macula-on RRD.[18] Increased FAZ represents ischemia, which correlates with worse visual acuity. This can be a useful biomarker to compare outcomes of different surgical techniques.

Ultra-widefield swept-source OCT

UWF-SS-OCT is a novel imaging system that delivers exceptional imaging capabilities for a wide range of retinal pathologies, extending even to the far periphery of the retina. In our recent study, we employed the newly available ultra-widefield confocal scanning laser ophthalmoscopy (CSLO) with single-capture integrated guided swept-source OCT to evaluate the retinal and choroidal response in the hours and days after laser retinopexy and cryopexy.[15] We observed microstructural alterations consistent with chorioretinal adhesion almost immediately at one hour after laser retinopexy, whereas such changes were only apparent on postprocedure day six in the case of cryopexy.[15]

We can't overstate the significance of these findings because they have a direct bearing on the success of RRD repair. The ability to achieve immediate adhesion following retinopexy can confer a distinct advantage, particularly in procedures such as PnR. UWF-SS-OCT also demonstrated that laser retinopexy was less traumatic, with preservation of the choroidal vasculature compared with cryopexy.

Fundus autofluorescence

Researchers have shown recent interest in retinal displacement detected by the presence of retinal vessel printings on FAF imaging (*Figure 3*) after RRD repair. This is another important imaging biomarker that has been associated with suboptimal functional outcomes after RRD repair when OCT doesn't find discernible abnormalities. Swiss investigators demonstrated that the presence of retinal displacement is associated with worse metamorphopsia.[19] Another large study by our group illustrated that the presence of retinal displacement was associated with worse aniseikonia.[20]

Researchers in the United Kingdom found that the amplitude of retinal displacement was associated with worse BCVA.[21] Because of these inconsistent findings, our group recently conducted a large comprehensive retrospective study that considered all imaging modalities and functional outcomes. Our findings indicated that the presence of retinal displacement had a significant impact on both BCVA and aniseikonia.[22]

Adaptive optics imaging

There's limited information regarding the morphological and functional restoration of photoreceptors after undergoing retinal detachment repair. Adaptive optics (AO) imaging of the retina allows for *en face* visualization of individual cones and quantitative evaluation of the cone mosaic (*Figure 4*). AO imaging can be another important biomarker that allows assessment of individual cone photoreceptors that can't be resolved with current commercial OCT technology due to its limited transverse resolution. This may be useful in assessing cone recovery and photoreceptor integrity after RRD repair.

Several authors have described improvements in cone density after RRD repair with time but also noted that it was still significantly lower compared to the healthy fellow eye.[23,24] Investigators have also demonstrated that cone density significantly correlated with visual acuity[23] and mean retinal sensitivity measured with microperimetry,[24] but no data to date exist on the association of changes to the cone mosaic with metamorphopsia or aniseikonia.

Increasing evidence suggests that the retina can be stretched, leading to retinal displacement following RRD repair, particularly related to the large gas bubble employed

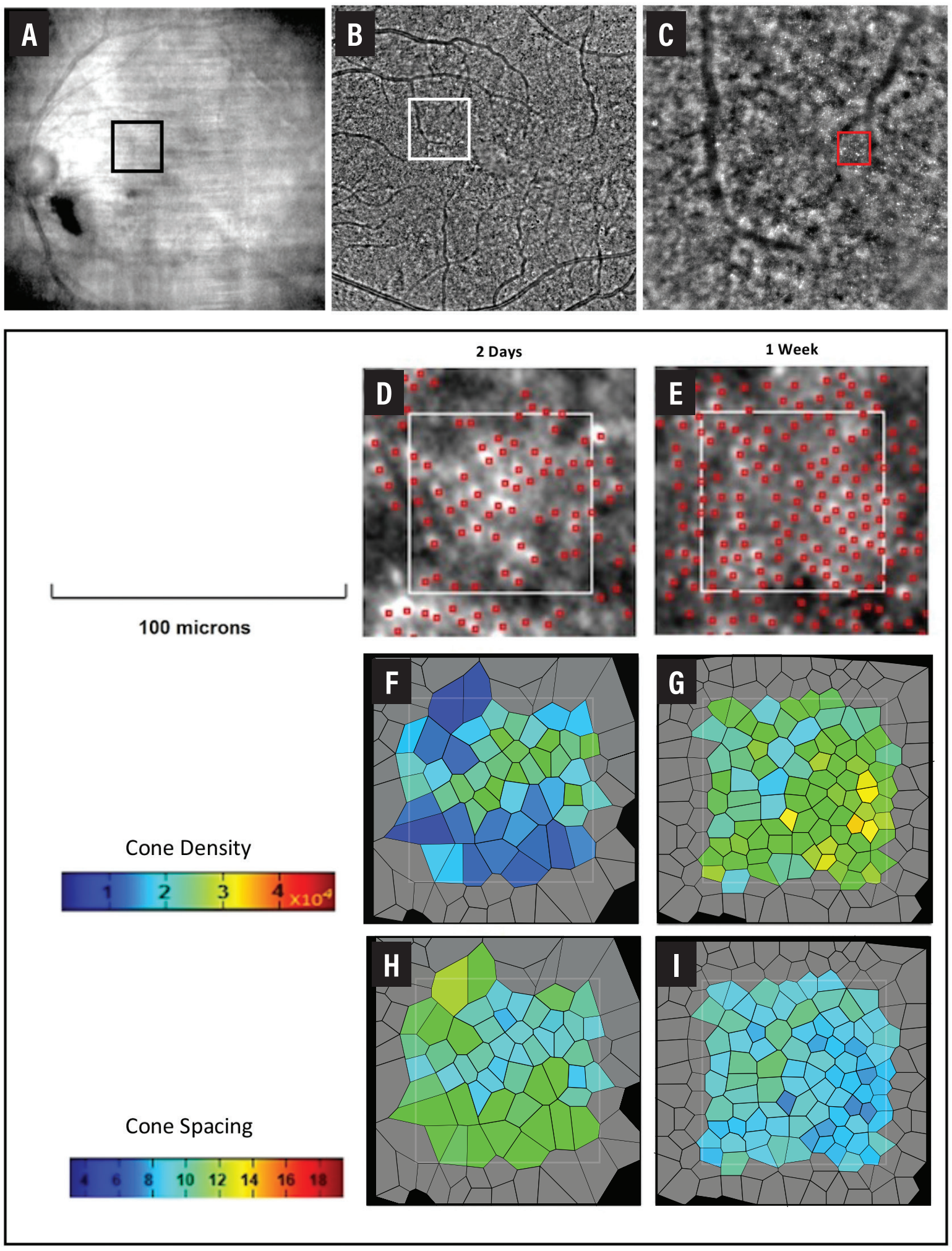

Figure 4. Adaptive optics images of a patient with fovea-split retinal detachment demonstrate visible cones as early as one week after pneumatic retinopexy (PnR). A) Near-infrared image of the macula two hours after face- down positioning post-PnR. B) Montage shows visible cones one week after PnR. C) The cone mosaic at eccentricity 2 degrees superonasal to the fovea. The analyzed region of interest (D, E) demonstrates a progressive increase in cone density (F, G) and reduction in cone spacing (H, I) following PnR. (Colors may differ from those seen in the clinic due to printing limitations.)

with PPV. Analysis of cone spacing with AO imaging may be a valuable imaging modality to provide additional information regarding changes to the photoreceptors immediately following RRD repair and its association with metamorphopsia or aniseikonia.

Our group recently demonstrated that it's possible to visualize and evaluate the macular cones using AO imaging as soon as one week after PnR.[25] During the early stages of structural restoration following RRD repair, AO imaging may demonstrate cone mosaic recovery. Cone density increase and cone spacing reduction seen even before outer retinal band restoration is observed on OCT. AO imaging may make it possible to assess the photoreceptors more effectively during the initial phases of recovery following RRD repair. This could potentially facilitate comparative analyses of the cone mosaic across different surgical techniques.

We believe the definition of a successful repair has undergone a significant shift from simply achieving anatomic reattachment with the least number of procedures to now encompassing the attainment of structural integrity of the reattachment.

Bottom line

In the current era of retinal detachment repair, we believe the definition of a successful repair has undergone a significant shift from simply achieving anatomic reattachment with the least number of procedures to now encompassing the attainment of structural integrity of the reattachment.

Multimodal imaging plays an essential role in achieving the integrity of the attachment because it allows for visualization of the physiological and pathophysiological reattachment, providing several novel biomarkers that can be used to assess outcomes and predict long-term prognosis for patients. These imaging biomarkers also provide useful outcome measures for future clinical trials that will compare various treatments for retinal detachment repair. RS

REFERENCES

1. Tornambe PE, Hilton GF. Pneumatic retinopexy. A multicenter randomized controlled clinical trial comparing pneumatic retinopexy with scleral buckling. The Retinal Detachment Study Group. Ophthalmology. 1989;96:772-783; discussion 784.
2. Heimann H, Bartz-Schmidt KU, Bornfeld N, Weiss C, Hilgers RD, Foerster MH. Scleral buckling versus primary vitrectomy in rhegmatogenous retinal detachment: a prospective randomized multicenter clinical study. Ophthalmology. 2007;114:2142-2154.
3. Hillier RJ, Felfeli T, Berger AR, et al. The Pneumatic Retinopexy versus Vitrectomy for the Management of Primary Rhegmatogenous Retinal Detachment Outcomes Randomized Trial (PIVOT). Ophthalmology. 2019;126:531-539.
4. Wakabayashi T, Oshima Y, Fujimoto H, et al. Foveal microstructure and visual acuity after retinal detachment repair: imaging analysis by Fourier-domain optical coherence tomography. Ophthalmology. 2009;116:519-528.
5. Okuda T, Higashide T, Sugiyama K. Metamorphopsia and outer retinal morphologic changes after successful vitrectomy surgery for macula-off rhegmatogenous retinal detachment. Retina. 2018;38:148-154.
6. Murakami T, Okamoto F, Sugiura Y, Okamoto Y, Hiraoka T, Oshika T. Changes in metamorphopsia and optical coherence tomography findings after successful retinal detachment surgery. Retina. 2018;38:684-691.
7. Okamoto F, Sugiura Y, Okamoto Y, et al. Metamorphopsia and optical coherence tomography findings after rhegmatogenous retinal detachment surgery. Am J Ophthalmol. 2014;157:214–220.e1. .
8. Okamoto F, Sugiura Y, Okamoto Y, Hiraoka T, Oshika T. Aniseikonia and foveal microstructure after retinal detachment surgery. Invest Ophthalmol Vis Sci. 2014;55:4880-4885.
9. Murakami T, Okamoto F, Sugiura Y, Okamoto Y, Hiraoka T, Oshika T. Changes in aniseikonia and influencing-factors following successful macula-off retinal detachment surgery. Sci Rep. 2019;9:11588.
10. van de Put MAJ, Vehof J, Hooymans JMM, Los LI. Postoperative metamorphopsia in macula-off rhegmatogenous retinal detachment: Associations with visual function, vision related quality of life, and optical coherence tomography findings. PLoS One. 2015;10:e0120543–e0120543.
11. Zhou C, Lin Q, Chen F. Prevalence and predictors of metamorphopsia after successful rhegmatogenous retinal detachment surgery: A cross-sectional, comparative study. Br J Ophthalmol. 2016;101:725–729.
12. Martins Melo I, Bansal A, Naidu S, et al. Morphologic Stages of rhegmatogenous retinal detachment assessed using swept-source OCT. Ophthalmol Retina. 2022:S2468-6530.
13. Bansal A, Lee WW, Felfeli T, Muni RH. Real-time in vivo assessment of retinal reattachment in humans using swept-source optical coherence tomography. Am J Ophthalmol. 2021;227:265-274.
14. Muni RH, Felfeli T, Sadda SR, et al. Postoperative photoreceptor integrity following pneumatic retinopexy vs pars plana vitrectomy for retinal detachment repair: A post hoc optical coherence tomography analysis from the Pneumatic Retinopexy Versus Vitrectomy for the Management of Primary Rhegmatogenous Retinal Detachment Outcomes Randomized Trial. JAMA Ophthalmol. 2021;139:620-627.
15. Lee WW, Muni RH. Single-capture ultra-widefield guided swept-source optical coherence tomography in the management of rhegmatogenous retinal detachment and associated peripheral vitreoretinal pathology. Br J Ophthalmol. 2022:bjophthalmol-2021-320149.
16. Lee WW, Bansal A, Sadda SR, et al. Outer retinal folds after pars plana vitrectomy vs. pneumatic retinopexy for retinal detachment repair: Post hoc analysis from PIVOT. Ophthalmol Retina. 2022;6:234-242.
17. Kobayashi M, Iwase T, Yamamoto K, et al. Association between photoreceptor regeneration and visual acuity following surgery for rhegmatogenous retinal detachment. Invest Ophthalmol Vis Sci 2016;57:889–898.
18. Francisconi CLM, Kim DT, Juncal V, et al. Foveal avascular zone area analysis using OCT angiography after pneumatic retinopexy for macula-off rhegmatogenous retinal detachment repair. J Vit Ret Dis. 2019;3:297-303.
19. Schawkat M, Valmaggia C, Lang C, Scholl HP, Guber J. Multimodal imaging for detecting metamorphopsia after successful retinal detachment repair. Graefes Arch Clin Exp Ophthalmol. 2020;258:57-61.
20. Francisconi CLM, Marafon SB, Figueiredo NA, et al. Retinal displacement after pneumatic retinopexy versus vitrectomy for rhegmatogenous retinal detachment (ALIGN). Ophthalmology. 2022;129:458-461.
21. Casswell EJ, Yorston D, Lee E, et al. Effect of face-down positioning vs support-the-break positioning after macula-involving retinal detachment repair: The PostRD Randomized Clinical Trial. JAMA Ophthalmol. 2020;138:634-642.
22. Lee WW, Francisconi CLM, Marafon SB, Juncal VR, Hillier RJ, Muni RH. Multimodal imaging predictors of functional outcomes following rhegmatogenous retinal detachment repair. Paper presented at the Association of Research in Vision and Ophthalmology annual meeting 2022; Denver, CO; May 1–4, 2022.
23. Potic J, Bergin C, Giacuzzo C, et al. Changes in visual acuity and photoreceptor density using adaptive optics after retinal detachment repair. Retina. 2020;40:376-386.
24. Reumueller A, Wassermann L, Salas M, et al. Morphologic and functional assessment of photoreceptors after macula-off retinal detachment with adaptive-optics OCT and microperimetry. Am J Ophthalmol. 2020;214:72-85.
25. Lee WW, Oquendo P, Muni RH. Early adaptive optics imaging after rhegmatogenous retinal detachment repair. Am J Ophthalmol. 2023;247:e3.

Update on mitochondrial stabilizers

Also from the Angiogenesis, Exudation, and Degeneration meeting, emerging treatments for nAMD and MacTel2, and a marker for anti-VEGF success in ROP.

By Ashkan M. Abbey, MD

Perhaps the most anticipated retina meeting of the first half of the year is Angiogenesis, Exudation, and Degeneration sponsored by Bascom Palmer Eye Institute, University of Miami Miller School of Medicine. Held again virtually last month, the program extended over two days with 11 different sessions on the latest findings for new therapies and strategies for retinal diseases.

Here, we review five abstracts that we think deserve a second look:

- An update on mitochondrial stabilizing agents in nonexudative age-related macular degeneration.
- Updated results of a trial of an axitinib intravitreal implant for neovascular AMD.
- Interim results of efdamrofusp alfa, also known at IBI302, for nAMD.
- Results from a Phase III trial of cell-based therapy for macular telangiectasia type 2.
- A deep dive into anti-VEGF trials in retinopathy of prematurity.



Potential markers for vision restoration in dry AMD

The mitochondrial stabilizing agents risuteganib (Allegro Pharmaceuticals) and elemipretide (Stealth Biotherapeutics) have demonstrated a signal for restoring functional vision in intermediate non-neovascular AMD patients with high levels of anatomical integrity, according to an analysis of trials for both agents.[1]

Mitochondrial defects are a hallmark of AMD. Baruch D. Kuppermann, MD, PhD, noted that elamipretide stabilizes cristae architecture and electron transport chain structure during oxidative stress by binding to cardiolipin in the inner mitochondrial membrane. Risuteganib preserves mitochondrial structures in retinal pigment epithelium cells under stress. Dr. Kuppermann is the Steinert Endowed Professor and chair of ophthalmology and director of the Gavin Herbert Eye Institute at the University of California Irvine.

He focused on the Phase IIa trial of risuteganib 1 mg (n=40), with 25 receiving treatment and 15 in the sham arm. The treatment group received risuteganib at baseline and 16 weeks, with an endpoint analysis at 28 weeks. The final endpoint evaluation for the sham group was 12 weeks, but at 16 weeks they crossed over to get a risuteganib injection.

Best-corrected visual acuity improvement in the treatment vs. sham arms were: ≥8-letter improvement, 48 vs. 7.1 percent (p=0.013); ≥10-letter improvement, 32 and 7.1 percent (p=0.118); and ≥20-letter improvement, 20 and 0 percent (p=0.139).

The analysis also captured predictors of response to risuteganib. While age, race/ethnicity and genotype didn't correlate with response, baseline optical coherence tomography findings did. Predictors include enhanced ellipsoid zone integrity, greater outer retinal thickness and decreased levels of geographic atrophy. Future clinical trials need to establish thresholds such as EZ and RPE thickness to cull study populations, Dr. Kuppermann said.

DISCLOSURE: Dr. Kuppermann is a consultant and researcher for Allegro Ophthalmics.



Bispecific antibody shows improvement in nAMD

Thirty-six-week results of a Phase II trial of the bispecific protein efdamrofusp alfa (IBI302, Innovent Biologics) demonstrated that 2- and 4-mg doses were well-tolerated in nAMD patients and led to improvements in BCVA and central subfield thickness.[2]

Xiaodong Sun, MD, professor of the National Clinical Research Center for Eye Disease and Shanghai General Hospital,

BIOS

Dr. Abbey is director of clinical research at Texas Retina Associates, Dallas, and a clinical assistant professor of ophthalmology at the University of Texas Southwestern Medical Center.

DISCLOSURES: Dr. Abbey is a consultant to Alcon, Allergan/AbbVie, Alimera Sciences, EyePoint Pharmaceuticals, Genentech/Roche, Novartis and Regeneron Pharmaceuticals.

described IBI302 as a novel bispecific decoy receptor fusion protein that targets vascular endothelial growth factor and the complement C3b/C4b pathways. He reported on a trial in China that enrolled 231 patients randomized 1:1:1 to IBI302 2 or 4 mg and aflibercept 2 mg. Eligibility criteria included choroidal neovascularization secondary to nAMD with BCVA 24 to 73 letters and age 50 years or older.

Changes in BCVA were 11.22 ± 10.8, 12.06 ± 11.75 and 12.46 ± 9.62 letters for the 2- and 4-mg IBI302 and aflibercept arms, respectively. The comparable proportion of patients who gained ≥10 letters were 45.45, 46.75 and 51.95 percent.

Reductions in CST were –132, –156 and –148 µm in the respective arms. Fibrosis rates were comparable across the three arms, but the rate of macular atrophy was lowest in the IBI302 4-mg arm, 2.6 percent vs. 5.19 and 7.79 percent in the IBI302 2-mg and aflibercept arms, respectively.

Safety profiles across all three arms were also comparable, Dr. Sun said. No cases of occlusive retinal vasculitis were reported. Full 52-week data are pending and a Phase III trial is upcoming.

DISCLOSURES: Dr. Sun is a consultant to Novartis, Roche, Bayer and Innovent.

Axitinib implant outcomes extend to 10 months

Updated results of a Phase I trial of an intravitreal hydrogel implant using the tyrosine kinase inhibitor (TKI) axitinib for treatment of nAMD showed that previously reported outcomes of 73 percent of treated patients remaining rescue free at seven months were maintained out to 10 months.[3]

Andrew A. Moshfeghi, MD, MBA, associate professor at the Keck School of Medicine, University of Southern California Roski Eye Institute, reported the interim 10-month data of the trial that randomized patients 3:1 to the axitinib implant OTX-TKI (Ocular Therapeutix) or aflibercept (n=20). Implant recipients had a 92 percent reduction in anti-VEGF injections at 10 months.

Axitinib is a highly selective inhibitor of all vascular endothelial and platelet-derived growth factors. The implant is delivered via a 25-gauge needle and gets resorbed in six to 12 months.

Inclusion criteria included response to anti-VEGF therapy and control of macular exudation at enrollment. Patients had their last anti-VEGF treatment one month before screening. OTX-TKI patients were dosed at baseline. Aflibercept patients received a sham dose at baseline. At one month, patients in both arms received the mandatory aflibercept injection. After that, aflibercept patients were treated every eight weeks. Rescue treatments were at the treating investigator's discretion.

Vision and CST changes were comparable between both groups. BCVA change from baseline to month 10 was –0.3 (standard deviation 5.1) letters and –0.8 (2.8) letters in the OTX-TKI and aflibercept arms. Mean change in CST was –1.3 (23.7) and –4.5 (4.4) µm in the respective arms.

No ocular or systemic serious adverse events were reported in either arm. The study is ongoing and the next data report is due after the 12-month endpoint. A separate Phase I trial is under way in diabetic retinopathy.

DISCLOSURES: Dr. Andrew Moshfeghi is a consultant to and shareholder in Ocular Therapeutix and Regeneron Pharmaceuticals.



Cell-based therapy to treat MacTel2

INT-501 (Neurotech) is an intraocular implant designed to deliver a ciliary neurotrophic factor in eyes with macular telangiectasia type 2 (MacTel). Topline 24-month data from two parallel Phase III trials showed the treatment significantly reduced progression of EZ loss at 24 months.[4]

The trials, the first to demonstrate effi-

Upated results of a Phase I trial of an intravitreal hydrogel implant using axitinib for nAMD showed that 73 percent of treated patients were rescue-free at 10 months.

cacy of a cell-based therapy delivering a neuroprotective cytokine to treat a neurodegenerative retinal disease, enrolled 224 patients. Entry criteria included a narrow range for EZ and absence of hyper-reflectivity on imaging, said Martin Friedlander, MD, PhD, professor of molecular medicine, Scripps Research Institute, chief of retina services at the Scripps Clinic, and president of the Lowy Medical Research Institute in La Jolla, California.

The progression rate of EZ area loss for control/sham patients was similar to that observed in the natural history study, ranging from 0.5 to 0.7 mm^2 at 24 months. In study B, the treatment group had a 27.8-percent reduction in the rate of EZ area loss compared to sham (p=0.0294). In the intent-to-treat analysis, the treatment group had a 29.2 percent reduction in EZ area loss rate vs. sham (p=0.021).

In study A, the effect at 24 months was even more pronounced for the treatment arm: a 55.9 percent reduction in progression in the per-protocol analysis (p<0.0001) and a 56.4 percent reduction in the intent-to-treat analysis (p<0.0001).

Next steps are to identify treatment responders or to show if earlier intervention has more impact on outcomes. An analysis of secondary endpoints and a meta-analysis are also planned, Dr. Friedlander said.

DISCLOSURE: Dr. Friedlander has no relationships to disclose.

The data demonstrate that ROP studies need to account for imbalances in absolute avascular retina area coupled with titrated PRP vs. fixed-dose anti-VEGF.

Avascular retina area potential target in ROP

The absolute avascular retina area in eyes with ROP may be a key factor for dosing anti-VEGF therapy to treat the inherited retinal disorder, according to an analysis of four clinical trials that compared anti-VEGF and laser panretinal photocoagulation.[5]

The analysis included the following trials: BEAT-ROP, with bevacizumab 0.5 mg; RAINBOW with ranibizumab 0.2 and 0.4 mg; and FIREFLEYE and BUTTERFLEYE, both with aflibercept 0.4 mg. Darius Moshfeghi, MD, professor of ophthalmology and chief of the retina division at Byers Eye Institute, Stanford University School of Medicine, Palo Alto, California, noted that the anti-VEGF medications "underperformed" expectations across the board. Only one arm in the BEAT-ROP trial—eyes with zone 1 ROP—met expectations.

BEAT-ROP is notable because it used 50 percent of the adult dose of bevacizumab, whereas the other trials used 20 to 40 percent of the adult dose. Meanwhile across all the trials, the efficacy of PRP improved over time. If done properly, the extent of laser treatment is titrated based on the amount of avascular retina, whereas anti-VEGF therapy is based on fixed dosing. "It's an unfair fight *a priori* when you start off because we're tailoring the laser but we're not tailoring the anti-VEGF therapy," Dr. Darius Moshfeghi said.

The data demonstrate that ROP studies need to account for imbalances in absolute avascular retina area coupled with titrated PRP vs. fixed-dose anti-VEGF. The findings may be applicable to other pediatric retinopathies, most notably familial exudative vitreoretinopathy (FEVR). However, studies of FEVR also need to account for the role of lipids as well as neovascularization and ischemia, he said.

DISCLOSURES: Dr. Darius Moshfeghi has no relevant relationships to disclose.

REFERENCES

1. Kuppermann BD. Reversing vision loss in dry AMD: Matching mechanism with the right patient population and stage of disease: Risuteganib for dry AMD. Paper presented at Angiogenesis, Exudation and Degeneration Meeting Virtual; February 10, 2023.
2 4. Sun X, Lu S, Jia H, Li T, Qian L. Primary endpoint results of a Phase II study of IBI302 (efdamrofusp alfa): A bispecific protein targeting VEGF & complement in patients with nAMD: Multi-center, randomized, active controlled trial. Paper presented at Angiogenesis, Exudation and Degeneration Meeting Virtual; February 11, 2023.
3. Moshfeghi AA, Couvillion SS, Eichenbaum DA, et al. Update on a hydrogel-based axitinib implant (OTX—TKI) for the treatment of neovascular age-related macular degeneration. Paper presented at Angiogenesis, Exudation and Degeneration Meeting Virtual; February 11, 2023.
4. Friedlander M. Results of the Phase 3 MacTel 2 CNTF trial: It worked!! Paper presented at Angiogenesis, Exudation and Degeneration Meeting Virtual; February 11, 2023.
5. Moshfeghi D, Wang SK, Moshfeghi HP, et al. Avascular retina as the risk factor for failure in BEAT ROP and anti-VEGF clinical trials. Paper presented at Angiogenesis, Exudation and Degeneration Meeting Virtual; February 11, 2023.

The physician as social media vanguard

When social media, public education and human rights collide, what is the physician's responsibility?

By Jayanth Sridhar, MD

Jayanth Sridhar, MD

It's an honor to take over the "Social Media Specialist" column from Dr. David Almeida. Dr. Almeida's prior work covered, and future articles in this section will cover, the *what, how* and *why* for optimizing social media in your practice.

One of the largest questions we face as physicians today is the question of *when*. That is, when do our Hippocratic oaths on nonmaleficence and beneficence compel us to speak out and use social media to educate the general public?

Social media's impact crosses international borders and simultaneously tantalizes with the possibility for mass public education on a scale previously impossible, while also shining a light on biased commercial influence, misinformation pundits and unscientific postulates masquerading as "need-to-know truths."

Lessons from the pandemic

The inability for laypeople to distinguish medical fact from fiction became a major issue in the early stages of the COVID-19 pandemic. Whether it was discussion of chemical bleach to treat a viral illness, murmuring that the pandemic was a hoax or questioning of the legitimacy of the COVID-19 vaccine, physicians were confronted with potentially life-threatening social media-driven narratives daily.

Many physicians appropriately viewed it as a responsibility to create posts, tweets and videos using their credentials and utilizing data-driven information to bring light to the social media darkness of false science.

Beyond basic medical advice

Does this scope extend beyond giving basic medical advice? Unfortunately, many examples of human rights violations exist in today's world. Relevant to ophthalmology, protests have run rampant in Iran in the wake of government crackdowns and killings of nonviolent dissenters. Government security forces have been instructed to shoot for the eyes of protesters with bird-shot bullets, resulting in severe ocular injuries.

Quotable

I foresee a responsibility and a privilege for us to be leaders for health not only on a scientific level, but also on a human rights and compassion level.

Moreover, police have been positioned in ambulances, hospitals and urgent care clinics to force physicians to deny medical attention to injured ophthalmology patients. As a result, Iranians are spreading misinformation on social media to avoid ophthalmology care following chemical or blunt injury. Laypeople even created DIY videos showing improper and unsterile techniques for removing periocular and intraocular foreign bodies at home.

Where we fit in

Where do physicians enter into this equation? In the end, we as ophthalmologists are committed by oath to protect health. At the very least, pushing educational content on social media on when to seek professional care for eye injuries is necessary.

I would argue that we should move beyond that to bring light to the plight of attacked and oppressed individuals throughout the world, including in Iran, when the line is crossed by an oppressor with the targeting of that most basic human right: health.

As social media continues to rapidly evolve and transform, we'll see more blurring of the lines of traditional professional boundaries.

I foresee a responsibility and a privilege for our profession to be leaders for health not only on a scientific level, but also on a human rights and compassion level.

BIO

Dr. Sridhar serves as *Retina Specialist Magazine's* Social Media Ambassador. He's an associate professor of clinical ophthalmology at Bascom Palmer Eye Institute, Miami.

DISCLOSURE: Dr. Sridhar is a consultant to Alcon, DORC, Genentech/Roche and Regeneron Pharmaceuticals.

Department Editor ***Richard Mark Kirkner***

A pill to head off worsening of DRSS

A Phase III trial is on deck for the oral Ref-1 inhibitor APX3330 after a Phase IIb study showed a potential benefit.

With Peter K. Kaiser, MD

Peter K. Kaiser, MD

APX3330 is an investigative oral treatment for diabetic eye disease that has demonstrated the potential to reduce proinflammatory and hypoxic signaling that contributes to diabetic retinopathy. Recently reported results from the ZETA-1 Phase IIb trial didn't meet the primary study endpoint, which was a more than two-step improvement in the Diabetic Retinopathy Severity Scale score; 8 percent of patients in both the treatment and placebo groups met the endpoint (p=0.93). However, the trial demonstrated a systemic and ocular safety profile.[1]

The Phase IIb trial, however, did meet what the trial sponsor and investigators say is an important secondary endpoint of preventing clinical meaningful progression of diabetic retinopathy after 24 weeks.

Here, Peter K. Kaiser, MD, professor at the Cole Eye Institute of the Cleveland Clinic, and a paid consultant and investigator for Ocuphire, follows up on his recent presentation of results from the Phase IIb trial.[1]

Q How would you describe the mechanism of action of APX3330?

A APX3330 is a Ref-1, or reduction-oxidation effector factor-1, inhibitor. Ref-1 is upstream of cis-1 alpha, which is upstream of vascular endothelial growth factor. In diabetes, Ref-1 is elevated, which increases cis-1 and VEGF, and we know what VEGF does.

Q What can you tell us about the design of the Zeta-1 Phase IIb trial?

A It evaluated the 600-mg daily dose of APX3330 compared with placebo. Patients had nonproliferative DR or moderate to severe proliferative DR. The primary outcome of a two-step improvement in DRSS is the same primary outcome for pivotal trials of ranibizumab and aflibercept.

Q What was the key secondary outcome?

A The secondary outcomes were things that people don't think about that often with trials in diabetic eye disease, but because APX3330 is a pill that affects both eyes, we evaluated both eyes and reported binocular results. That meant a three-step improvement or worsening of DRSS in both eyes.

However, because APX3330 has been evaluated in so many other previous studies in other diseases, a dose-escalation study wasn't needed. We already knew the 600-mg dose was more than adequate and safe.

Q What else did the trial reveal about APX3330?

A Interestingly, in the fellow eye there was a very a large trend of 27 percent vs. 5 percent for placebo that met the primary endpoint, but this wasn't statistically significant (p=0.2).

Q What about improvement or worsening of DRSS?

A In the APX3330 group, no patients had the ≥3-step worsening in DRSS at 24 weeks in both eyes compared to 16 percent in the placebo group (p=0.04). There was also a trend in the opposite direction: 11 percent of APX3330 patients had a ≥3-step improvement vs. 6 percent (p=0.38).

Q What's next in the development of APX3330?

A Because of the Phase II results, the primary outcome for the Phase III trial would be prevention of three-step worsening DRSS. So the next step is to get sign-off on the Phase III registration study. RS

REFERENCE

1, Kaiser PK. Efficacy and safety data for APX3330, a novel oral drug candidate for DR/DME from the ZETA-1 Phase 2b trial. Paper presented at Angiogenesis, Exudation and Degeneration Meeting Virtual; February 11, 2023.

BIO

Peter K. Kaiser, MD, is a professor at the Cole Eye Institute of the Cleveland Clinic.

DISCLOSURE: Dr. Kaiser is a paid consultant and investigator for Ocuphire Pharma.

EYLEA®
(aflibercept) Injection
For Intravitreal Injection

BRIEF SUMMARY—Please see the EYLEA full Prescribing Information available on HCP.EYLEA.US for additional product information.

1 INDICATIONS AND USAGE

EYLEA is a vascular endothelial growth factor (VEGF) inhibitor indicated for the treatment of patients with:

Neovascular (Wet) Age-Related Macular Degeneration (AMD), Macular Edema Following Retinal Vein Occlusion (RVO), Diabetic Macular Edema (DME), Diabetic Retinopathy (DR).

4 CONTRAINDICATIONS

4.1 Ocular or Periocular Infections

EYLEA is contraindicated in patients with ocular or periocular infections.

4.2 Active Intraocular Inflammation

EYLEA is contraindicated in patients with active intraocular inflammation.

4.3 Hypersensitivity

EYLEA is contraindicated in patients with known hypersensitivity to aflibercept or any of the excipients in EYLEA. Hypersensitivity reactions may manifest as rash, pruritus, urticaria, severe anaphylactic/anaphylactoid reactions, or severe intraocular inflammation.

5 WARNINGS AND PRECAUTIONS

5.1 Endophthalmitis and Retinal Detachments

Intravitreal injections, including those with EYLEA, have been associated with endophthalmitis and retinal detachments [*see Adverse Reactions (6.1)*]. Proper aseptic injection technique must always be used when administering EYLEA. Patients should be instructed to report any symptoms suggestive of endophthalmitis or retinal detachment without delay and should be managed appropriately [*see Patient Counseling Information (17)*].

5.2 Increase in Intraocular Pressure

Acute increases in intraocular pressure have been seen within 60 minutes of intravitreal injection, including with EYLEA [*see Adverse Reactions (6.1)*]. Sustained increases in intraocular pressure have also been reported after repeated intravitreal dosing with vascular endothelial growth factor (VEGF) inhibitors. Intraocular pressure and the perfusion of the optic nerve head should be monitored and managed appropriately.

5.3 Thromboembolic Events

There is a potential risk of arterial thromboembolic events (ATEs) following intravitreal use of VEGF inhibitors, including EYLEA. ATEs are defined as nonfatal stroke, nonfatal myocardial infarction, or vascular death (including deaths of unknown cause). The incidence of reported thromboembolic events in wet AMD studies during the first year was 1.8% (32 out of 1824) in the combined group of patients treated with EYLEA compared with 1.5% (9 out of 595) in patients treated with ranibizumab; through 96 weeks, the incidence was 3.3% (60 out of 1824) in the EYLEA group compared with 3.2% (19 out of 595) in the ranibizumab group. The incidence in the DME studies from baseline to week 52 was 3.3% (19 out of 578) in the combined group of patients treated with EYLEA compared with 2.8% (8 out of 287) in the control group; from baseline to week 100, the incidence was 6.4% (37 out of 578) in the combined group of patients treated with EYLEA compared with 4.2% (12 out of 287) in the control group. There were no reported thromboembolic events in the patients treated with EYLEA in the first six months of the RVO studies.

6 ADVERSE REACTIONS

The following potentially serious adverse reactions are described elsewhere in the labeling:
- Hypersensitivity [*see Contraindications (4.3)*]
- Endophthalmitis and retinal detachments [*see Warnings and Precautions (5.1)*]
- Increase in intraocular pressure [*see Warnings and Precautions (5.2)*]
- Thromboembolic events [*see Warnings and Precautions (5.3)*]

6.1 Clinical Trials Experience

Because clinical trials are conducted under widely varying conditions, adverse reaction rates observed in the clinical trials of a drug cannot be directly compared to rates in other clinical trials of the same or another drug and may not reflect the rates observed in practice.

A total of 2980 patients treated with EYLEA constituted the safety population in eight phase 3 studies. Among those, 2379 patients were treated with the recommended dose of 2 mg. Serious adverse reactions related to the injection procedure have occurred in <0.1% of intravitreal injections with EYLEA including endophthalmitis and retinal detachment. The most common adverse reactions (≥5%) reported in patients receiving EYLEA were conjunctival hemorrhage, eye pain, cataract, vitreous detachment, vitreous floaters, and intraocular pressure increased.

Neovascular (Wet) Age-Related Macular Degeneration (AMD). The data described below reflect exposure to EYLEA in 1824 patients with wet AMD, including 1223 patients treated with the 2-mg dose, in 2 double-masked, controlled clinical studies (VIEW1 and VIEW2) for 24 months (with active control in year 1).

Safety data observed in the EYLEA group in a 52-week, double-masked, Phase 2 study were consistent with these results.

Table 1: Most Common Adverse Reactions (≥1%) in Wet AMD Studies

	Baseline to Week 52		Baseline to Week 96	
Adverse Reactions	EYLEA (N=1824)	Active Control (ranibizumab) (N=595)	EYLEA (N=1824)	Control (ranibizumab) (N=595)
Conjunctival hemorrhage	25%	28%	27%	30%
Eye pain	9%	9%	10%	10%
Cataract	7%	7%	13%	10%
Vitreous detachment	6%	6%	8%	8%
Vitreous floaters	6%	7%	8%	10%
Intraocular pressure increased	5%	7%	7%	11%
Ocular hyperemia	4%	8%	5%	10%
Corneal epithelium defect	4%	5%	5%	6%
Detachment of the retinal pigment epithelium	3%	3%	5%	5%
Injection site pain	3%	3%	3%	4%
Foreign body sensation in eyes	3%	4%	4%	4%
Lacrimation increased	3%	1%	4%	2%
Vision blurred	2%	2%	4%	3%
Intraocular inflammation	2%	3%	3%	4%
Retinal pigment epithelium tear	2%	1%	2%	2%
Injection site hemorrhage	1%	2%	2%	2%
Eyelid edema	1%	2%	2%	3%
Corneal edema	1%	1%	1%	1%
Retinal detachment	<1%	<1%	1%	1%

Less common serious adverse reactions reported in <1% of the patients treated with EYLEA were hypersensitivity, retinal tear, and endophthalmitis.

Macular Edema Following Retinal Vein Occlusion (RVO). The data described below reflect 6 months exposure to EYLEA with a monthly 2 mg dose in 218 patients following central retinal vein occlusion (CRVO) in 2 clinical studies (COPERNICUS and GALILEO) and 91 patients following branch retinal vein occlusion (BRVO) in one clinical study (VIBRANT).

Table 2: Most Common Adverse Reactions (≥1%) in RVO Studies

	CRVO		BRVO	
Adverse Reactions	EYLEA (N=218)	Control (N=142)	EYLEA (N=91)	Control (N=92)
Eye pain	13%	5%	4%	5%
Conjunctival hemorrhage	12%	11%	20%	4%
Intraocular pressure increased	8%	6%	2%	0%
Corneal epithelium defect	5%	4%	2%	0%
Vitreous floaters	5%	1%	1%	0%
Ocular hyperemia	5%	3%	2%	2%
Foreign body sensation in eyes	3%	5%	3%	0%
Vitreous detachment	3%	4%	2%	0%
Lacrimation increased	3%	4%	3%	0%
Injection site pain	3%	1%	1%	0%
Vision blurred	1%	<1%	1%	1%
Intraocular inflammation	1%	1%	0%	0%
Cataract	<1%	1%	5%	0%
Eyelid edema	<1%	1%	1%	0%

Less common adverse reactions reported in <1% of the patients treated with EYLEA in the CRVO studies were corneal edema, retinal tear, hypersensitivity, and endophthalmitis.

Diabetic Macular Edema (DME) and Diabetic Retinopathy (DR). The data described below reflect exposure to EYLEA in 578 patients with DME treated with the 2-mg dose in 2 double-masked, controlled clinical studies (VIVID and VISTA) from baseline to week 52 and from baseline to week 100.

Table 3: Most Common Adverse Reactions (≥1%) in DME Studies

	Baseline to Week 52		Baseline to Week 100	
Adverse Reactions	EYLEA (N=578)	Control (N=287)	EYLEA (N=578)	Control (N=287)
Conjunctival hemorrhage	28%	17%	31%	21%
Eye pain	9%	6%	11%	9%
Cataract	8%	9%	19%	17%
Vitreous floaters	6%	3%	8%	6%
Corneal epithelium defect	5%	3%	7%	5%
Intraocular pressure increased	5%	3%	9%	5%
Ocular hyperemia	5%	6%	5%	6%
Vitreous detachment	3%	3%	8%	6%
Foreign body sensation in eyes	3%	3%	3%	3%
Lacrimation increased	3%	2%	4%	2%
Vision blurred	2%	2%	3%	4%
Intraocular inflammation	2%	<1%	3%	1%
Injection site pain	2%	<1%	2%	<1%
Eyelid edema	<1%	1%	2%	1%

Less common adverse reactions reported in <1% of the patients treated with EYLEA were hypersensitivity, retinal detachment, retinal tear, corneal edema, and injection site hemorrhage.

Safety data observed in 269 patients with nonproliferative diabetic retinopathy (NPDR) through week 52 in the PANORAMA trial were consistent with those seen in the phase 3 VIVID and VISTA trials (see Table 3 above).

6.2 Immunogenicity

As with all therapeutic proteins, there is a potential for an immune response in patients treated with EYLEA. The immunogenicity of EYLEA was evaluated in serum samples. The immunogenicity data reflect the percentage of patients whose test results were considered positive for antibodies to EYLEA in immunoassays. The detection of an immune response is highly dependent on the sensitivity and specificity of the assays used, sample handling, timing of sample collection, concomitant medications, and underlying disease. For these reasons, comparison of the incidence of antibodies to EYLEA with the incidence of antibodies to other products may be misleading.

In the wet AMD, RVO, and DME studies, the pre-treatment incidence of immunoreactivity to EYLEA was approximately 1% to 3% across treatment groups. After dosing with EYLEA for 24-100 weeks, antibodies to EYLEA were detected in a similar percentage range of patients. There were no differences in efficacy or safety between patients with or without immunoreactivity.

8 USE IN SPECIFIC POPULATIONS

8.1 Pregnancy

Risk Summary

Adequate and well-controlled studies with EYLEA have not been conducted in pregnant women. Aflibercept produced adverse embryofetal effects in rabbits, including external, visceral, and skeletal malformations. A fetal No Observed Adverse Effect Level (NOAEL) was not identified. At the lowest dose shown to produce adverse embryofetal effects, systemic exposures (based on AUC for free aflibercept) were approximately 6 times higher than AUC values observed in humans after a single intravitreal treatment at the recommended clinical dose [*see Animal Data*].

Animal reproduction studies are not always predictive of human response, and it is not known whether EYLEA can cause fetal harm when administered to a pregnant woman. Based on the anti-VEGF mechanism of action for aflibercept, treatment with EYLEA may pose a risk to human embryofetal development. EYLEA should be used during pregnancy only if the potential benefit justifies the potential risk to the fetus.

All pregnancies have a background risk of birth defect, loss, or other adverse outcomes. The background risk of major birth defects and miscarriage for the indicated population is unknown. In the U.S. general population, the estimated background risk of major birth defects and miscarriage in clinically recognized pregnancies is 2-4% and 15-20%, respectively.

Data

Animal Data

In two embryofetal development studies, aflibercept produced adverse embryofetal effects when administered every three days during organogenesis to pregnant rabbits at intravenous doses ≥3 mg per kg, or every six days during organogenesis at subcutaneous doses ≥0.1 mg per kg.

Adverse embryofetal effects included increased incidences of postimplantation loss and fetal malformations, including anasarca, umbilical hernia, diaphragmatic hernia, gastroschisis, cleft palate, ectrodactyly, intestinal atresia, spina bifida, encephalomeningocele, heart and major vessel defects, and skeletal malformations (fused vertebrae, sternebrae, and ribs; supernumerary vertebral arches and ribs; and incomplete ossification). The maternal No Observed Adverse Effect Level (NOAEL) in these studies was 3 mg per kg. Aflibercept produced fetal malformations at all doses assessed in rabbits and the fetal NOAEL was not identified. At the lowest dose shown to produce adverse embryofetal effects in rabbits (0.1 mg per kg), systemic exposure (AUC) of free aflibercept was approximately 6 times higher than systemic exposure (AUC) observed in humans after a single intravitreal dose of 2 mg.

8.2 Lactation

Risk Summary

There is no information regarding the presence of aflibercept in human milk, the effects of the drug on the breastfed infant, or the effects of the drug on milk production/excretion. Because many drugs are excreted in human milk, and because the potential for absorption and harm to infant growth and development exists, EYLEA is not recommended during breastfeeding.

The developmental and health benefits of breastfeeding should be considered along with the mother's clinical need for EYLEA and any potential adverse effects on the breastfed child from EYLEA.

8.3 Females and Males of Reproductive Potential

Contraception

Females of reproductive potential are advised to use effective contraception prior to the initial dose, during treatment, and for at least 3 months after the last intravitreal injection of EYLEA.

Infertility

There are no data regarding the effects of EYLEA on human fertility. Aflibercept adversely affected female and male reproductive systems in cynomolgus monkeys when administered by intravenous injection at a dose approximately 1500 times higher than the systemic level observed humans with an intravitreal dose of 2 mg. A No Observed Adverse Effect Level (NOAEL) was not identified. These findings were reversible within 20 weeks after cessation of treatment.

8.4 Pediatric Use

The safety and effectiveness of EYLEA in pediatric patients have not been established.

8.5 Geriatric Use

In the clinical studies, approximately 76% (2049/2701) of patients randomized to treatment with EYLEA were ≥65 years of age and approximately 46% (1250/2701) were ≥75 years of age. No significant differences in efficacy or safety were seen with increasing age in these studies.

17 PATIENT COUNSELING INFORMATION

In the days following EYLEA administration, patients are at risk of developing endophthalmitis or retinal detachment. If the eye becomes red, sensitive to light, painful, or develops a change in vision, advise patients to seek immediate care from an ophthalmologist [*see Warnings and Precautions (5.1)*].

Patients may experience temporary visual disturbances after an intravitreal injection with EYLEA and the associated eye examinations [*see Adverse Reactions (6)*]. Advise patients not to drive or use machinery until visual function has recovered sufficiently.

REGENERON

Manufactured by:
Regeneron Pharmaceuticals, Inc.
777 Old Saw Mill River Road
Tarrytown, NY 10591

Issue Date: 08/2019
Initial U.S. Approval: 2011

Based on the August 2019 EYLEA® (aflibercept) Injection full Prescribing Information.

EYL.20.09.0052

References: 1. EYLEA® (aflibercept) Injection full U.S. Prescribing Information. Regeneron Pharmaceuticals, Inc. August 2022. **2.** Kaiser PK, Singer M, Tolentino M, et al. Long-term safety and visual outcome of intravitreal aflibercept in neovascular age-related macular degeneration: VIEW 1 extension study. *Ophthalmol Retina.* 2017;1(4):304-313. doi:10.1016/j.oret.2017.01.004 **3.** Jaffe GJ, Kaiser PK, Thompson D, et al. Differential response to anti-VEGF regimens in age-related macular degeneration patients with early persistent retinal fluid. *Ophthalmology.* 2016;123(9):1856-1864. doi:10.1016/j.ophtha.2016.05.016 **4.** Data on file. Regeneron Pharmaceuticals, Inc.